A 42-year-old woman comes to the office due to a 2-month history of an intermittent burning sensation in her chest with an occasional simultaneous acidic taste at the back of her throat. The symptoms occur soon after she eats a meal. The patient has no shortness of breath, lightheadedness, nausea, vomiting, or weight loss. She has no other medical conditions. The patient has smoked a pack of cigarettes daily for the last 10 years but does not use alcohol. Family history is unremarkable. Vital signs are within normal limits. BMI is 32 kg/m^2. Physical examination shows no abnormalities. Urine pregnancy test is negative. Smoking cessation is discussed, and a medication is prescribed for treatment of her symptoms. The patient returns in 2 weeks for a follow-up visit and reports near-complete resolution of her symptoms. Which of the following is the most likely mechanism of action of this drug?

A. Blockade of gastrin receptors

B. Creation of a cytoprotective layer in the stomach

C. Inhibition of H^+/K^+ ATPase activity

D. Inhibition of synthesis of gastrin

E. Prostaglandin-mediated inhibition of acid secretion

Submit

A 42-year-old woman comes to the office due to a 2-month history of an intermittent burning sensation in her chest with an occasional simultaneous acidic taste at the back of her throat. The symptoms occur soon after she eats a meal. The patient has no shortness of breath, lightheadedness, nausea, vomiting, or weight loss. She has no other medical conditions. The patient has smoked a pack of cigarettes daily for the last 10 years but does not use alcohol. Family history is unremarkable. Vital signs are within normal limits. BMI is 32 kg/m^2. Physical examination shows no abnormalities. Urine pregnancy test is negative. Smoking cessation is discussed, and a medication is prescribed for treatment of her symptoms. The patient returns in 2 weeks for a follow-up visit and reports near-complete resolution of her symptoms. Which of the following is the most likely mechanism of action of this drug?

- A. Blockade of gastrin receptors (0%)
- B. Creation of a cytoprotective layer in the stomach (0%)
- ✓ C. Inhibition of H^+/K^+ ATPase activity (95%)
- D. Inhibition of synthesis of gastrin (0%)
- E. Prostaglandin-mediated inhibition of acid secretion (1%)

Omitted
Correct answer
C

95%
Answered correctly

02 secs
Time Spent

03/13/2020
Last Updated

Explanation

Parietal cell acid secretion

Vagus nerve

1
2
3
4
5
6
7
8
9
10
11
12
13
14
15
16
17
18
19
20
21
22
23
24
25
26
27
28
29
30
31

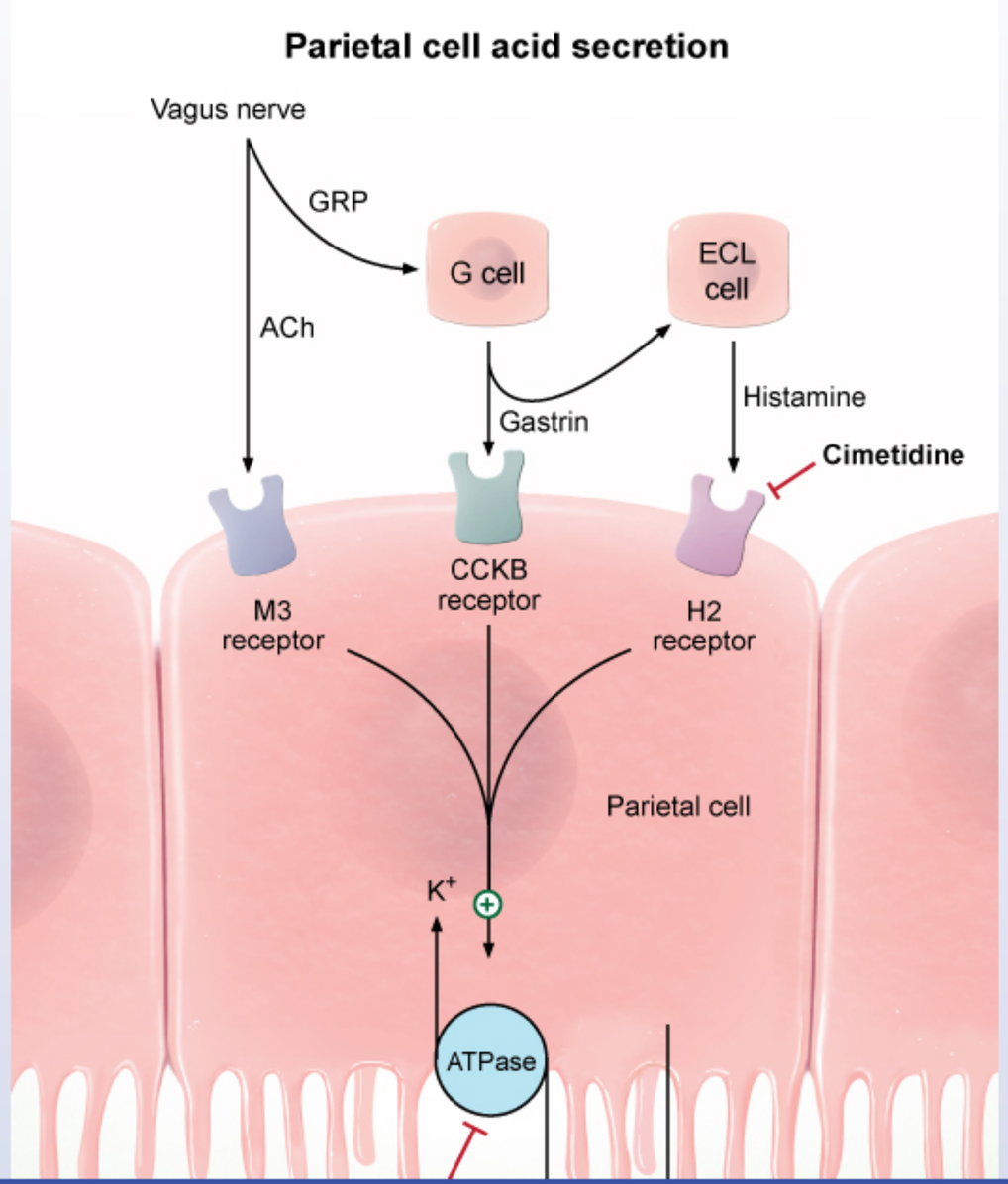

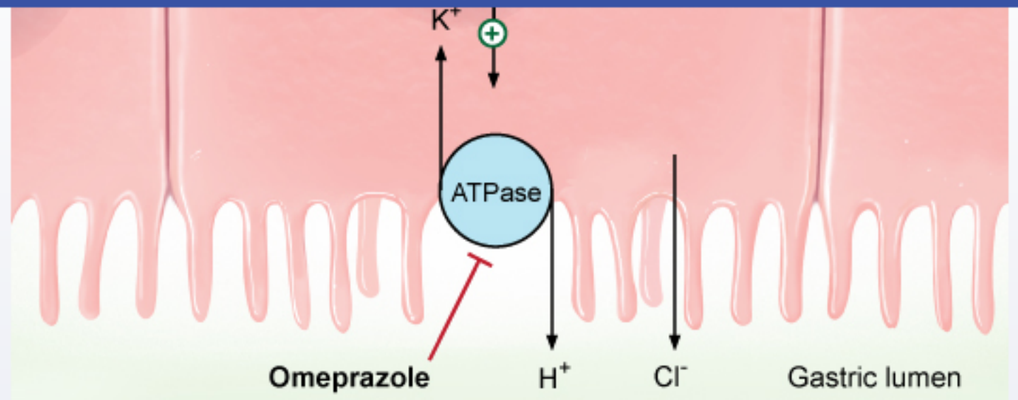

ACh = acetylcholine; **CCKB** = cholecystokinin B; **ECL** = enterochromaffin like; **GRP** = gastrin-releasing peptide; **M3** = muscarinic.
©UWorld

This patient's heartburn is likely related to gastroesophageal reflux disease (GERD), a common disorder that occurs when gastric acid refluxes into the esophagus. Management consists of lifestyle and dietary modifications (eg, weight loss, avoidance of tobacco) as well as medications that suppress gastric acid secretion.

Proton pump inhibitors (PPIs) (eg, pantoprazole, omeprazole) are the most effective inhibitors of gastric acid secretion. They bind to and irreversibly **inhibit the H^+/K^+ ATPase** on parietal cells. Side effects are related to elevated gastric pH and include an increased risk of *Clostridioides difficile* and nutritional deficiencies (eg, calcium, magnesium, iron).

Although less potent than PPIs, **histamine 2 receptor antagonists** (eg, famotidine, cimetidine) are also used as first-line therapy for GERD. They inhibit gastric acid secretion by targeting histamine receptors on parietal cells. These medications are less side effect–prone than PPIs; however, they have a slower onset of action, and tachyphylaxis is common.

(Choice A) Gastrin, a hormone released from G cells, binds to cholecystokinin (CCK) B receptors and stimulates gastric acid secretion both directly (through binding on parietal cells) and indirectly (through binding on enterochromaffin-like cells to increase histamine release). CCK receptor antagonists are not routinely used in clinical practice.

(Choice B) Sucralfate forms a viscous paste in the stomach, providing a cytoprotective layer that prevents the diffusion of gastric acid. It is less effective than PPIs and is typically used as an adjunctive medication for peptic ulcer disease.

Proton pump inhibitors (PPIs) (eg, pantoprazole, omeprazole) are the most effective inhibitors of gastric acid secretion. They bind to and irreversibly **inhibit the H^+/K^+ ATPase** on parietal cells. Side effects are related to elevated gastric pH and include an increased risk of *Clostridioides difficile* and nutritional deficiencies (eg, calcium, magnesium, iron).

Although less potent than PPIs, **histamine 2 receptor antagonists** (eg, famotidine, cimetidine) are also used as first-line therapy for GERD. They inhibit gastric acid secretion by targeting histamine receptors on parietal cells. These medications are less side effect–prone than PPIs; however, they have a slower onset of action, and tachyphylaxis is common.

(Choice A) Gastrin, a hormone released from G cells, binds to cholecystokinin (CCK) B receptors and stimulates gastric acid secretion both directly (through binding on parietal cells) and indirectly (through binding on enterochromaffin-like cells to increase histamine release). CCK receptor antagonists are not routinely used in clinical practice.

(Choice B) Sucralfate forms a viscous paste in the stomach, providing a cytoprotective layer that prevents the diffusion of gastric acid. It is less effective than PPIs and is typically used as an adjunctive medication for peptic ulcer disease.

(Choice D) Octreotide is a somatostatin analogue that inhibits gastrin synthesis (as well as many other gastrointestinal hormones). It is sometimes used in Zollinger-Ellison syndrome, but is not routinely used for GERD.

(Choice E) Misoprostol is a prostaglandin E1 analogue that binds prostaglandin receptors on parietal cells, reducing gastric acid production and inducing secretion of mucus and bicarbonate. Misoprostol can be used to prevent NSAID–induced gastric ulcers, but is less helpful for treating GERD; its significant uterotonic effects (eg, uterine contractions, cervical ripening) also limit its use in women of childbearing age.

Educational objective:
Management of gastroesophageal reflux disease includes lifestyle and dietary modifications (eg, weight loss, tobacco avoidance) and medications such as proton pump inhibitors (PPIs) (eg, pantoprazole, omeprazole) or histamine 2 receptor antagonists (eg, ranitidine). PPIs irreversibly inhibit the H^+/K^+ ATPase on parietal cells, which decreases gastric acid secretion.

Pharmacology	Gastrointestinal & Nutrition	Gastroesophageal reflux disease
Subject	System	Topic

Copyright © UWorld. All rights reserved.

A 72-year-old man comes to the office for evaluation of constipation. His stools have been hard and pelletlike for as long as he can remember. The patient has a bowel movement every 3-4 days and frequently strains when using the bathroom. He has had associated abdominal discomfort but no hematochezia, melena, vomiting, or unexpected weight changes. The symptoms have not improved despite fiber supplementation. Vital signs are within normal limits. The abdomen is mildly distended with decreased bowel sounds. In addition to increasing water consumption, the patient is advised to try bisacodyl for constipation. What is the primary mechanism of action of this medication?

A. Decreases surface tension of stool

B. Draws water into the stool by creating an osmotic gradient

C. Draws water into the stool by directly activating chloride channels

D. Improves peristalsis by blocking mu-receptors

E. Improves peristalsis by stimulating enteric nerves

Submit

A 72-year-old man comes to the office for evaluation of constipation. His stools have been hard and pelletlike for as long as he can remember. The patient has a bowel movement every 3-4 days and frequently strains when using the bathroom. He has had associated abdominal discomfort but no hematochezia, melena, vomiting, or unexpected weight changes. The symptoms have not improved despite fiber supplementation. Vital signs are within normal limits. The abdomen is mildly distended with decreased bowel sounds. In addition to increasing water consumption, the patient is advised to try bisacodyl for constipation. What is the primary mechanism of action of this medication?

- A. Decreases surface tension of stool (12%)
- B. Draws water into the stool by creating an osmotic gradient (40%)
- C. Draws water into the stool by directly activating chloride channels (9%)
- D. Improves peristalsis by blocking mu-receptors (10%)
- ✓ E. Improves peristalsis by stimulating enteric nerves (27%)

Omitted
Correct answer
E

27%
Answered correctly

02 secs
Time Spent

02/18/2020
Last Updated

Explanation

Commonly used medications for constipation	
Bulk-forming laxatives (eg, fiber supplements)	• Binds luminal water to decrease consistency of stool • Side effects: flatulence, abdominal distension
Osmotic laxatives	

Explanation

Commonly used medications for constipation	
Bulk-forming laxatives (eg, fiber supplements)	• Binds luminal water to decrease consistency of stool • Side effects: flatulence, abdominal distension
Osmotic laxatives (eg, polyethylene glycol, magnesium hydroxide, lactulose)	• Osmotically active agent that draws water into the lumen • Side effects: electrolyte disturbances, bloating
Surfactant (eg, docusate)	• Decreases stool surface tension, enabling water to enter stool • Side effects: rare
Stimulant laxatives (eg, bisacodyl, senna)	• Activates enteric nerves in myenteric plexus to stimulate peristalsis • Side effects: abdominal cramping, electrolyte disturbances
Chloride channel agonist (eg, lubiprostone)	• Causes chloride efflux into intestinal lumen, which is followed by sodium and water • Side effects: headache, nausea
Peripherally acting μ-opioid receptor antagonists (eg, methylnaltrexone)	• Counteracts inhibitory effect of opioids on peristalsis • Side effects: rare (does not cause opiate withdrawal)

*All constipation medications can cause diarrhea at high doses.

Bisacodyl is a **stimulant laxative** that is commonly used to treat constipation and neurogenic bowel; it is also indicated for bowel preparation prior to endoscopic procedures (eg, colonoscopy).

Bisacodyl is hydrolyzed in the colon to its active form, which directly **stimulates the enteric nerves** within the colonic myenteric plexus, thereby **increasing peristalsis** and enhancing colonic motility. It also has some minor secretory effects in the small intestine, where it increases production of cyclic AMP, indirectly increasing secretion of chloride and bicarbonate while inhibiting sodium resorption. Side effects include

Bisacodyl is a **stimulant laxative** that is commonly used to treat constipation and neurogenic bowel; it is also indicated for bowel preparation prior to endoscopic procedures (eg, colonoscopy).

Bisacodyl is hydrolyzed in the colon to its active form, which directly **stimulates the enteric nerves** within the colonic myenteric plexus, thereby **increasing peristalsis** and enhancing colonic motility. It also has some minor secretory effects in the small intestine, where it increases production of cyclic AMP, indirectly increasing secretion of chloride and bicarbonate while inhibiting sodium resorption. Side effects include diarrhea, mild abdominal cramping, and electrolyte disturbances (eg, hypokalemia). Other stimulant laxatives include senna and castor oil.

(Choice A) Docusate reduces the surface tension of stool, enabling water and fat to enter and soften it.

(Choice B) Magnesium hydroxide, polyethylene glycol, and lactulose are osmotically active agents that are poorly absorbed by the intestines. These medications draw water into the intestinal lumen, thereby softening stool and making it easier to pass.

(Choice C) Lubiprostone is an agonist of the ClC-2 chloride channel located on the apical membrane of the intestine, which increases chloride secretion into the intestinal lumen. Sodium and water follow chloride into the lumen, resulting in increased intestinal fluid content.

(Choice D) Methylnaltrexone is a mu-opioid receptor antagonist designed to treat opioid-induced constipation. It does not cross the blood-brain barrier, which allows it to be used without inducing opiate-withdrawal symptoms.

Educational objective:
Bisacodyl is a commonly used stimulant laxative that stimulates the enteric neurons within the colonic myenteric plexus, thereby increasing peristaltic activity and enhancing colonic motility.

References

- Management of constipation in older adults.
- Treatment of chronic constipation: current pharmacologic approaches and future directions.

Pharmacology	Gastrointestinal & Nutrition	Constipation
Subject	System	Topic

Copyright © UWorld. All rights reserved.

A 78-year-old male nursing home resident is brought to the physician because of abdominal pain and discomfort. He has a history of advanced dementia and is only partially able to verbalize his symptoms. He has had intermittent abdominal discomfort for years, with no other related symptoms. He denies diarrhea and rectal bleeding but has not had a bowel movement in approximately 5 days. The patient is largely bed-bound, and only has minimal activity with the help of nurses and physical therapists. Past regular colonoscopies have shown only benign lesions. His other medical problems include dementia, coronary artery disease, hypertension, spinal stenosis, and osteoarthritis of his hips and knees. Abdominal examination does not show tenderness, masses, or hepatosplenomegaly, although fullness is appreciated. The remainder of the examination shows no abnormalities. Polyethylene glycol is administered and produces a bowel movement within 24 hours. The mechanism of action of polyethylene glycol in this patient is most similar to the pathophysiology of which of the following disorders?

- A. Irritable bowel syndrome
- B. Crohn's disease
- C. Lactase deficiency
- D. Carcinoid syndrome
- E. Rectal prolapse

Submit

A 78-year-old male nursing home resident is brought to the physician because of abdominal pain and discomfort. He has a history of advanced dementia and is only partially able to verbalize his symptoms. He has had intermittent abdominal discomfort for years, with no other related symptoms. He denies diarrhea and rectal bleeding but has not had a bowel movement in approximately 5 days. The patient is largely bed-bound, and only has minimal activity with the help of nurses and physical therapists. Past regular colonoscopies have shown only benign lesions. His other medical problems include dementia, coronary artery disease, hypertension, spinal stenosis, and osteoarthritis of his hips and knees. Abdominal examination does not show tenderness, masses, or hepatosplenomegaly, although fullness is appreciated. The remainder of the examination shows no abnormalities. Polyethylene glycol is administered and produces a bowel movement within 24 hours. The mechanism of action of polyethylene glycol in this patient is most similar to the pathophysiology of which of the following disorders?

- A. Irritable bowel syndrome (11%)
- B. Crohn's disease (2%)
- ✓ C. Lactase deficiency (76%)
- D. Carcinoid syndrome (8%)
- E. Rectal prolapse (1%)

Omitted
Correct answer
C

76%
Answered correctly

01 sec
Time Spent

05/07/2020
Last Updated

Explanation

Constipation is common in elderly, debilitated patients as well as those on chronic opiate therapy. Because lifestyle changes are not an option in patients such as this one, constipation in this population is commonly treated with osmotic laxatives (e.g., magnesium citrate, polyethylene glycol)

Constipation is common in elderly, debilitated patients as well as those on chronic opiate therapy. Because lifestyle changes are not an option in patients such as this one, constipation in this population is commonly treated with osmotic laxatives (e.g., magnesium citrate, polyethylene glycol), stool softeners, and enemas.

Osmotic laxatives are nonabsorbable or poorly absorbable substances that attract water into the intestinal lumen, thus distending the intestinal wall and increasing peristalsis. The laxative effect is usually fairly rapid. Magnesium hydroxide (and other magnesium-containing compounds, such as magnesium citrate) is another osmotic laxative that is often used, although its efficacy is questionable and there is not enough evidence to support its widespread use.

Lactase deficiency is a disease state characterized by osmotic diarrhea. Inherited or acquired deficiency of the intestinal brush border enzyme lactase (i.e., disaccharidase) causes inability to break down lactose into glucose and galactose. Undigested lactose is a nonabsorbable osmotic substance, and its accumulation in the small intestine leads to an increase in the secretion of water and electrolytes into the intestinal lumen. Lactase deficiency (i.e., lactose intolerance) presents with abdominal pain and distension and watery diarrhea. Abdominal pain and distention result from the metabolism of lactose by normal gut flora through fermentation, which causes the production of gas. The symptoms resolve when milk-containing products are eliminated from the diet.

(Choice A) Irritable bowel syndrome is a functional intestinal disorder that presents with diarrhea alternating with constipation, abdominal pain, and distention without organic cause. Fecal water and electrolyte content are normal.

(Choice B) Diarrhea in Crohn's disease is of the secretory type, which is characterized by high electrolyte content due to poor absorption and increased losses from the inflamed intestinal mucosa.

(Choice D) Diarrhea in carcinoid syndrome is secretory and high in electrolytes.

(Choice E) Rectal prolapse is a protrusion of rectal mucosa through the anus associated with pregnancy and constipation; it can also be seen in severe diarrhea. Another important cause of rectal prolapse is cystic fibrosis, particularly in children.

Educational objective:
Polyethylene glycol is an osmotic laxative. Diarrhea associated with lactase deficiency is also osmotic and occurs due to accumulation of nonabsorbable lactose in the intestinal lumen. Magnesium hydroxide (and other magnesium-containing compounds, such as magnesium citrate) is another osmotic laxative that is often used, although its efficacy is questionable and there is not enough evidence to support its widespread use.

lactase (i.e., disaccharidase) causes inability to break down lactose into glucose and galactose. Undigested lactose is a nonabsorbable osmotic substance, and its accumulation in the small intestine leads to an increase in the secretion of water and electrolytes into the intestinal lumen. Lactase deficiency (i.e., lactose intolerance) presents with abdominal pain and distension and watery diarrhea. Abdominal pain and distention result from the metabolism of lactose by normal gut flora through fermentation, which causes the production of gas. The symptoms resolve when milk-containing products are eliminated from the diet.

(Choice A) Irritable bowel syndrome is a functional intestinal disorder that presents with diarrhea alternating with constipation, abdominal pain, and distention without organic cause. Fecal water and electrolyte content are normal.

(Choice B) Diarrhea in Crohn's disease is of the secretory type, which is characterized by high electrolyte content due to poor absorption and increased losses from the inflamed intestinal mucosa.

(Choice D) Diarrhea in carcinoid syndrome is secretory and high in electrolytes.

(Choice E) Rectal prolapse is a protrusion of rectal mucosa through the anus associated with pregnancy and constipation; it can also be seen in severe diarrhea. Another important cause of rectal prolapse is cystic fibrosis, particularly in children.

Educational objective:
Polyethylene glycol is an osmotic laxative. Diarrhea associated with lactase deficiency is also osmotic and occurs due to accumulation of nonabsorbable lactose in the intestinal lumen. Magnesium hydroxide (and other magnesium-containing compounds, such as magnesium citrate) is another osmotic laxative that is often used, although its efficacy is questionable and there is not enough evidence to support its widespread use.

References

- Approach to fecal incontinence and constipation in older hospitalized patients.
- Review of the treatment options for chronic constipation.

Pharmacology	Gastrointestinal & Nutrition	Constipation
Subject	System	Topic

Copyright © UWorld. All rights reserved.

A 62-year-old man is hospitalized with severe abdominal pain and diarrhea after a recent urinary tract infection. Six months ago, the patient had an episode of *Clostridium difficile* colitis after being treated for pneumonia. Medical history is also significant for diverticulitis and upper gastrointestinal tract bleeding. The patient is allergic to penicillin. An appropriate workup confirms *C difficile* colitis. The patient is placed on an oral macrocyclic antibiotic that inhibits the sigma subunit of RNA polymerase. Which of the following agents was most likely administered to this patient?

A. Doxycycline

B. Fidaxomicin

C. Metronidazole

D. Neomycin

E. Vancomycin

Submit

A 62-year-old man is hospitalized with severe abdominal pain and diarrhea after a recent urinary tract infection. Six months ago, the patient had an episode of *Clostridium difficile* colitis after being treated for pneumonia. Medical history is also significant for diverticulitis and upper gastrointestinal tract bleeding. The patient is allergic to penicillin. An appropriate workup confirms *C difficile* colitis. The patient is placed on an oral macrocyclic antibiotic that inhibits the sigma subunit of RNA polymerase. Which of the following agents was most likely administered to this patient?

- A. Doxycycline (10%)
- ✓ B. Fidaxomicin (33%)
- C. Metronidazole (35%)
- D. Neomycin (8%)
- E. Vancomycin (11%)

Omitted
Correct answer
B

33%
Answered correctly

01 sec
Time Spent

03/29/2020
Last Updated

Explanation

Treatment options for ***Clostridium difficile* infection** (CDI) typically include oral vancomycin or fidaxomicin. **Fidaxomicin** is a macrocyclic antibiotic (related to macrolides) that **inhibits** the sigma subunit of **RNA polymerase**, leading to protein synthesis impairment and cell death (**bactericidal** activity against *C difficile*). It is administered orally and has minimal systemic absorption, resulting in high fecal concentrations. It also has a narrow spectrum of activity with a lesser effect on normal colonic flora than vancomycin.

(Choice A) Doxycycline binds to the 30S ribosomal subunit and is effective in clostridial skin infections (eg, *C perfringens, C septicum*), but it is

Explanation

Treatment options for ***Clostridium difficile* infection** (CDI) typically include oral vancomycin or fidaxomicin. **Fidaxomicin** is a macrocyclic antibiotic (related to macrolides) that **inhibits** the sigma subunit of **RNA polymerase**, leading to protein synthesis impairment and cell death (**bactericidal** activity against *C difficile*). It is administered orally and has minimal systemic absorption, resulting in high fecal concentrations. It also has a narrow spectrum of activity with a lesser effect on normal colonic flora than vancomycin.

(Choice A) Doxycycline binds to the 30S ribosomal subunit and is effective in clostridial skin infections (eg, *C perfringens, C septicum*), but it is not effective for treatment of CDI.

(Choice C) Metronidazole interacts with DNA in anaerobic organisms, disrupting DNA structure and causing strand breakage. Intravenous metronidazole can be a useful adjunct in patients with severe CDI (eg, megacolon, ileus, hypotension), since these patients often have delayed passage of oral antibiotics.

(Choice D) Neomycin is a bactericidal aminoglycoside that inhibits the 30S ribosomal subunit. It can be used to treat hepatic encephalopathy or diarrhea due to *Escherichia coli* and as surgical prophylaxis for gastrointestinal procedures. However, it is not effective against *C difficile*.

(Choice E) Oral vancomycin has minimal systemic absorption and is often used to treat initial or recurrent CDI. It inhibits cell wall synthesis and is bacteriostatic against *C difficile* at the concentrations typically used for CDI treatment.

Educational objective:
Clostridium difficile infection can be treated with oral vancomycin or fidaxomicin. Fidaxomicin is a macrocyclic antibiotic that inhibits RNA polymerase. It is bactericidal against *C difficile*.

References

- Fidaxomicin: a novel macrocyclic antibiotic approved for treatment of Clostridium difficile infection.
- Bactericidal activity of telavancin, vancomycin and metronidazole against Clostridium difficile.
- Clinical practice guidelines for Clostridium difficile infection in adults and children: 2017 update by the Infectious Diseases Society of America (IDSA) and Society for Healthcare Epidemiology of America (SHEA).

A 52-year-old postmenopausal woman comes to the office for evaluation of several months of episodic abdominal discomfort and nausea, especially after a fatty meal. She has no past medical history and does not use tobacco, alcohol, or illicit drugs. Her BMI is 33 kg/m^2. Physical examination shows a soft, nontender abdomen with normal bowel sounds. Liver span is 8 cm. Murphy sign is negative. Abdominal x-ray reveals no calcifications, but abdominal ultrasound shows a small, non-obstructing gallstone. The patient prefers nonoperative management. Which of the following would best treat this patient's condition?

- A. Bile acid supplement
- B. Cholestyramine therapy
- C. Estrogen replacement therapy
- D. Fenofibrate therapy
- E. Iron chelation therapy
- F. Phosphate-binding agent
- G. Rapid weight loss

Submit

A 52-year-old postmenopausal woman comes to the office for evaluation of several months of episodic abdominal discomfort and nausea, especially after a fatty meal. She has no past medical history and does not use tobacco, alcohol, or illicit drugs. Her BMI is 33 kg/m^2. Physical examination shows a soft, nontender abdomen with normal bowel sounds. Liver span is 8 cm. Murphy sign is negative. Abdominal x-ray reveals no calcifications, but abdominal ultrasound shows a small, non-obstructing gallstone. The patient prefers nonoperative management. Which of the following would best treat this patient's condition?

- ✓ A. Bile acid supplement (46%)
- B. Cholestyramine therapy (31%)
- C. Estrogen replacement therapy (2%)
- D. Fenofibrate therapy (8%)
- E. Iron chelation therapy (0%)
- F. Phosphate-binding agent (4%)
- G. Rapid weight loss (5%)

Omitted
Correct answer
A

46%
Answered correctly

02 secs
Time Spent

02/15/2020
Last Updated

Explanation

Formation of cholesterol gallstones

1
2
3
4
5
6
7
8
9
10
11
12
13
14
15
16
17
18
19
20
21
22
23
24
25
26
27
28
29
30
31

Formation of cholesterol gallstones

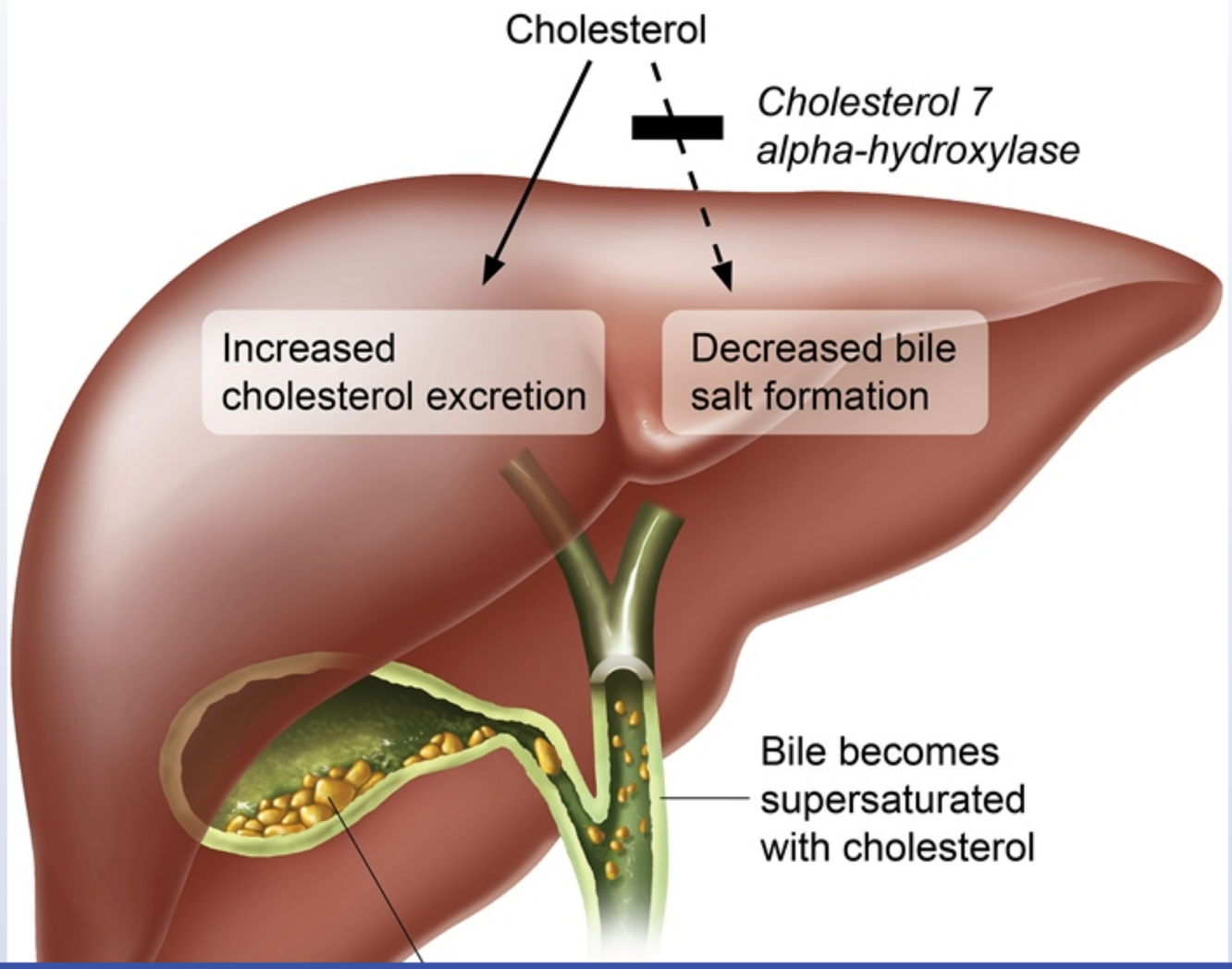

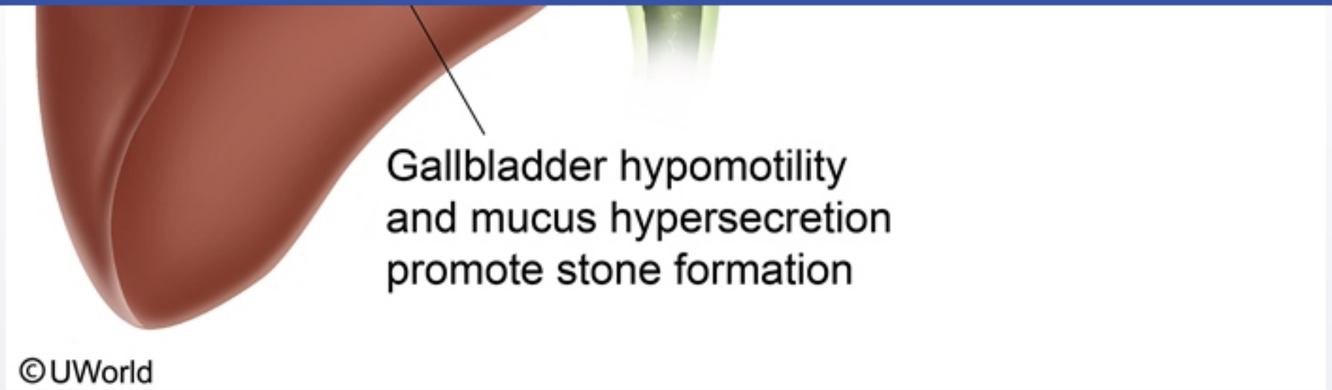

Cholesterol gallstones are the most common type of gallstone. They are primarily composed of cholesterol monohydrate crystals but can contain variable amounts of calcium salts, bilirubin, and mucin. Normally, bile acids and phospholipids solubilize the cholesterol to prevent stone formation. Decreased amounts of bile acids and phospholipids can cause the bile to become supersaturated with cholesterol, allowing it to crystallize and form cholesterol gallstones. Risk factors for stone formation include increasing age, obesity, excessive bile salt loss (eg, terminal ileum disease), and female sex.

Cholecystectomy is the preferred treatment for symptomatic gallstones. However, medical therapy is an option in patients refusing surgery or with high surgical risk. Administration of **hydrophilic bile acids** (eg, ursodeoxycholic acid) reduces cholesterol secretion and increases biliary bile acid concentration. This improves cholesterol solubility and **promotes gallstone dissolution**. Although the response to medical therapy is good in patients with mild symptoms and small stones, there is a high rate of gallstone recurrence.

(Choice B) Bile acid sequestrants (eg, cholestyramine) decrease enterohepatic recirculation of bile acids (increase gallstone risk). However, they also stimulate the conversion of cholesterol to bile acids and increase biliary motility (decrease gallstone risk). The net result is no significant change in the risk of gallstones.

(Choice C) Estrogen increases cholesterol secretion and progesterone reduces bile acid secretion, ultimately causing bile to become supersaturated with cholesterol. Progesterone also slows gallbladder emptying, which causes bile stasis and further promotes gallstone formation.

(Choice D) Fibrates increase cholesterol content in bile, which increases the risk of gallstones.

patients with mild symptoms and small stones, there is a high rate of gallstone recurrence.

(Choice B) Bile acid sequestrants (eg, cholestyramine) decrease enterohepatic recirculation of bile acids (increase gallstone risk). However, they also stimulate the conversion of cholesterol to bile acids and increase biliary motility (decrease gallstone risk). The net result is no significant change in the risk of gallstones.

(Choice C) Estrogen increases cholesterol secretion and progesterone reduces bile acid secretion, ultimately causing bile to become supersaturated with cholesterol. Progesterone also slows gallbladder emptying, which causes bile stasis and further promotes gallstone formation.

(Choice D) Fibrates increase cholesterol content in bile, which increases the risk of gallstones.

(Choice E) Iron chelation therapy is used to treat iron overload syndromes but has no significant effect on gallstones.

(Choice F) Phosphate-binding agents can lower serum phosphate in chronic kidney disease and dialysis patients but do not significantly affect gallstones.

(Choice G) Very low-calorie diets with decreased caloric intake and rapid weight loss can lead to bile stasis and increased cholesterol mobilization, increasing the risk of gallstone formation.

Educational objective:
Medical therapy to dissolve cholesterol gallstones is an option in patients refusing cholecystectomy or with high surgical risk. Hydrophilic bile acids (eg, ursodeoxycholic acid) improve cholesterol solubility by reducing the amount of cholesterol secreted into the bile and increasing biliary bile acid concentration.

References

- Targets for current pharmacologic therapy in cholesterol gallstone disease.

Pharmacology	Gastrointestinal & Nutrition	Gallstone disease
Subject	System	Topic

Copyright © UWorld. All rights reserved.

A 56-year-old man comes to the emergency department because of sudden onset of severe, diffuse abdominal pain. The patient has experienced 3 months of epigastric pain that has been refractive to proton-pump inhibitor therapy. Physical examination reveals an exquisitely tender, rigid abdomen with rebound tenderness. Abdominal radiographs reveal free air under the diaphragm. Supportive therapy is initiated. Exploratory laparotomy reveals a large, perforated gastric ulcer with features suggestive of malignancy. He undergoes partial gastrectomy with gastrojejunostomy. Long-term supplementation with which of the following is most important in this patient?

A. Ascorbic acid

B. Biotin

C. Iron

D. Pantothenic acid

E. Pyridoxine

Submit

A 56-year-old man comes to the emergency department because of sudden onset of severe, diffuse abdominal pain. The patient has experienced 3 months of epigastric pain that has been refractive to proton-pump inhibitor therapy. Physical examination reveals an exquisitely tender, rigid abdomen with rebound tenderness. Abdominal radiographs reveal free air under the diaphragm. Supportive therapy is initiated. Exploratory laparotomy reveals a large, perforated gastric ulcer with features suggestive of malignancy. He undergoes partial gastrectomy with gastrojejunostomy. Long-term supplementation with which of the following is most important in this patient?

- A. Ascorbic acid (4%)
- B. Biotin (5%)
- ✓ C. Iron (72%)
- D. Pantothenic acid (4%)
- E. Pyridoxine (13%)

Omitted
Correct answer
C

72%
Answered correctly

02 secs
Time Spent

04/08/2020
Last Updated

Explanation

1
2
3
4
5
6
7
8
9
10
11
12
13
14
15
16
17
18
19
20
21
22
23
24
25
26
27
28
29
30
31

Billroth II

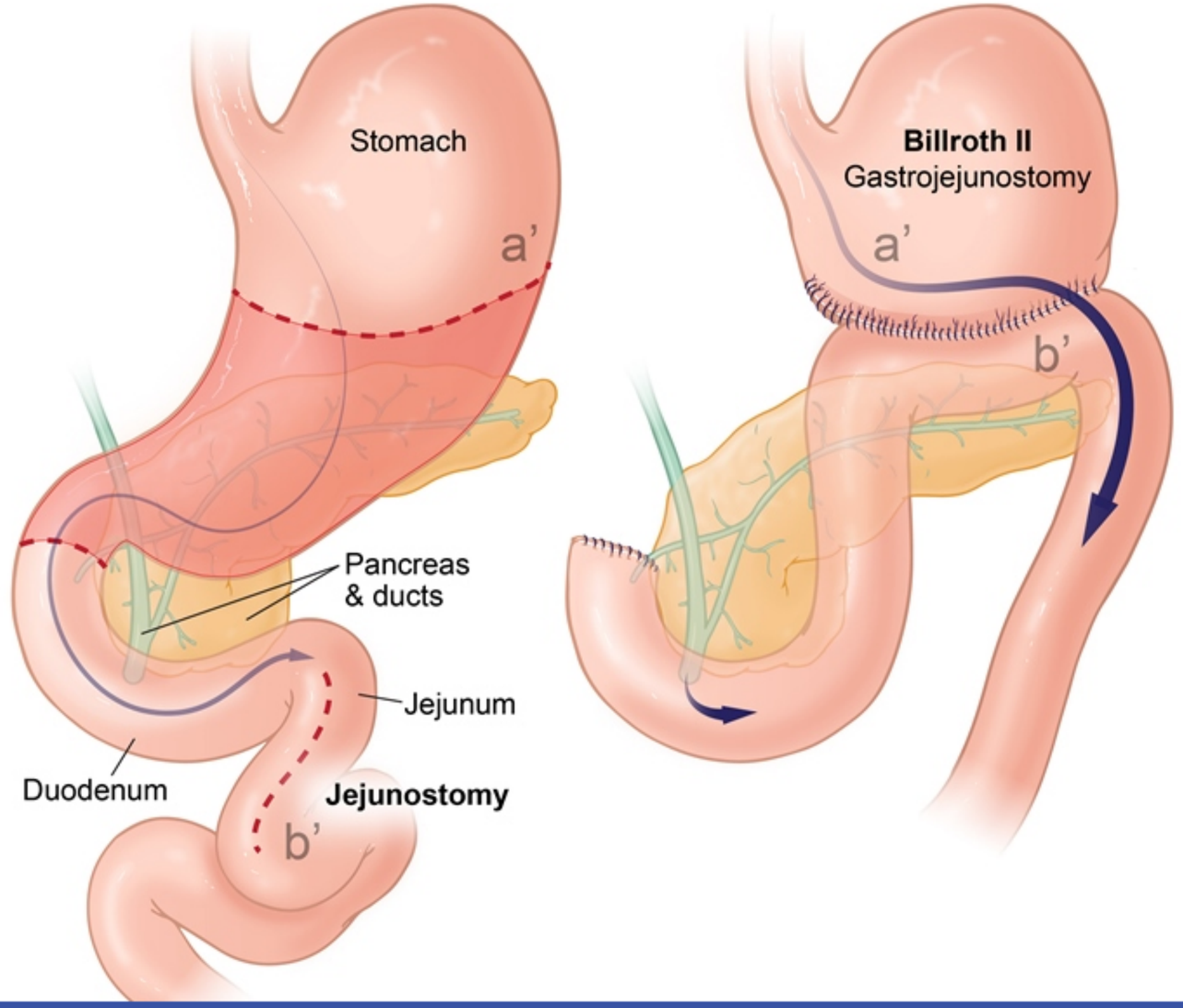

©UWorld

Partial gastrectomy with **gastrojejunostomy** is most often performed to treat **complicated peptic ulcer disease** (eg, perforation, malignancy, gastric outlet obstruction) or ulcers refractory to medical management. In a Billroth II gastrojejunostomy, the gastric antrum is removed to decrease gastrin production and for histopathologic evaluation. A side-to-side anastomosis is then made between the jejunum and the gastric body, bypassing the duodenum and proximal jejunum.

Iron absorption occurs predominantly in the **duodenum and proximal jejunum**, and bypass of this segment of small bowel results in iron deficiency **anemia**. The post-surgical decrease in gastric acidity also diminishes iron absorption and may contribute to iron deficiency in these patients. Treatment is accomplished with pharmacologic **iron supplementation**, which allows for adequate iron absorption at secondary absorption sites in the distal small bowel. Vitamin B_{12}, folate, fat-soluble vitamins (especially vitamin D), and calcium are also primarily absorbed in the small bowel and deficiencies in these may be observed following gastrojejunostomy.

(Choice A) Although ascorbic acid (vitamin C) can increase the bioavailability of nonheme iron, vitamin C supplementation would not be enough to counteract the effect of decreased iron absorption post-gastrojejunostomy.

(Choices B and D) Biotin (vitamin B_7) and pantothenic acid (vitamin B_5) are absorbed in the small and large intestine via the sodium-dependent multivitamin transporter. Deficiency of either of these vitamins is rare and not associated with gastric bypass procedures.

(Choice E) Pyridoxine (vitamin B_6) absorption occurs in the jejunum and the ileum by passive diffusion and is not typically affected by gastrojejunostomy.

Educational objective:
Iron absorption occurs predominantly in the duodenum and proximal jejunum. Bypass of this segment of small bowel by gastrojejunostomy results in iron deficiency anemia that can be corrected with pharmacologic iron supplementation. Malabsorption of vitamin B_{12}, folate, fat-soluble vitamins (especially vitamin D), and calcium may also be observed following gastric bypass procedures.

Pharmacology	Gastrointestinal & Nutrition	GI surgery
Subject	System	Topic

Copyright © UWorld. All rights reserved.

1
2
3
4
5
6
7
8
9
10
11
12
13
14
15
16
17
18
19
20
21
22
23
24
25
26
27
28
29
30
31

A 72-year-old man comes to the office due to constipation. His stools have become increasingly hard, small-volume, and difficult to pass. This has been associated with bloating but not vomiting. Symptoms have not improved despite fiber supplementation, polyethylene glycol, and bisacodyl. The patient was recently diagnosed with metastatic pancreatic cancer and was prescribed palliative chemotherapy 2 months ago. His cancer causes severe abdominal pain, which requires high-dose oxycodone to control. Vital signs are within normal limits. The abdomen is mildly distended with decreased bowel sounds. Which of the following medications acts as a μ-opioid receptor antagonist that could alleviate this patient's constipation without inducing withdrawal symptoms?

A. Diphenoxylate
B. Loperamide
C. Lubiprostone
D. Methylnaltrexone
E. Naloxone

Submit

A 72-year-old man comes to the office due to constipation. His stools have become increasingly hard, small-volume, and difficult to pass. This has been associated with bloating but not vomiting. Symptoms have not improved despite fiber supplementation, polyethylene glycol, and bisacodyl. The patient was recently diagnosed with metastatic pancreatic cancer and was prescribed palliative chemotherapy 2 months ago. His cancer causes severe abdominal pain, which requires high-dose oxycodone to control. Vital signs are within normal limits. The abdomen is mildly distended with decreased bowel sounds. Which of the following medications acts as a μ-opioid receptor antagonist that could alleviate this patient's constipation without inducing withdrawal symptoms?

- A. Diphenoxylate (10%)
- B. Loperamide (32%)
- C. Lubiprostone (7%)
- ✓ D. Methylnaltrexone (40%)
- E. Naloxone (8%)

Omitted
Correct answer
D

40%
Answered correctly

02 secs
Time Spent

02/20/2020
Last Updated

Explanation

Anticonstipation agents	
Bulk-forming laxatives (eg, fiber supplements)	• Binds luminal water to decrease consistency of stool • Side effects: flatulence, abdominal distension

Anticonstipation agents	
Bulk-forming laxatives (eg, fiber supplements)	• Binds luminal water to decrease consistency of stool • Side effects: flatulence, abdominal distension
Osmotic laxatives (eg, polyethylene glycol, magnesium hydroxide, lactulose)	• Osmotically active agent that draws water into the lumen • Side effects: electrolyte disturbances, bloating
Surfactant (eg, docusate)	• Decreases stool surface tension, enabling water to enter stool • Side effects: rare
Stimulant laxatives (eg, bisacodyl, senna)	• Activates enteric nerves in myenteric plexus to stimulate peristalsis • Side effects: abdominal cramping, electrolyte disturbances
Chloride channel agonist (eg, lubiprostone)	• Causes chloride efflux into intestinal lumen, which is followed by sodium and water • Side effects: headache, nausea
Peripherally acting μ-opioid receptor antagonists (eg, methylnaltrexone)	• Counteracts inhibitory effect of opioids on peristalsis • Side effects: rare (does not cause opiate withdrawal)

*All constipation medications can cause diarrhea at high doses.

This patient has **opioid-induced constipation** (OIC). Opiates (eg, oxycodone) exert their analgesic effects by binding to opiate receptors in the central and peripheral nervous systems, reducing nociceptive transmission and the perception of pain. Constipation, the most common side effect of opiate therapy, occurs due to the activation of **μ-opiate receptors** in the gastrointestinal tract. This results in decreased intestinal peristaltic activity and inhibition of ion and fluid secretion, leading to desiccated, pellet-like stool. Unlike many other opiate side effects, tolerance to constipation does not readily occur. Therefore, all patients on opiate therapy should be considered for prophylactic laxative therapy (eg, docusate, polyethylene glycol, bisacodyl).

This patient has **opioid-induced constipation** (OIC). Opiates (eg, oxycodone) exert their analgesic effects by binding to opiate receptors in the central and peripheral nervous systems, reducing nociceptive transmission and the perception of pain. Constipation, the most common side effect of opiate therapy, occurs due to the activation of **μ-opiate receptors** in the gastrointestinal tract. This results in decreased intestinal peristaltic activity and inhibition of ion and fluid secretion, leading to desiccated, pellet-like stool. Unlike many other opiate side effects, tolerance to constipation does not readily occur. Therefore, all patients on opiate therapy should be considered for prophylactic laxative therapy (eg, docusate, polyethylene glycol, bisacodyl).

Those with refractory OIC may benefit from **methylnaltrexone**, a peripherally acting **μ-opioid receptor antagonist** that reverses the anti-peristaltic effect of opiates. It does not cross the blood-brain barrier; therefore, it **does not induce** opiate-related **withdrawal symptoms**, allowing for treatment of OIC without disrupting analgesic effects.

(Choices A and B) Diphenoxylate and loperamide are both opiate-based medications designed to inhibit peristalsis in the gastrointestinal tract. These medications are used to treat diarrhea and would worsen this patient's constipation.

(Choice C) Lubiprostone is a chloride channel agonist that increases intestinal secretions. Although it is not a μ-opioid receptor antagonist, it can be used to treat OIC and would not put patients at risk for opiate-related withdrawal.

(Choice E) Naloxone is also an opioid receptor antagonist; however, unlike methylnaltrexone, naloxone crosses the blood-brain barrier. It induces symptoms of withdrawal and reversal of analgesia and is used to treat acute opioid toxicity (eg, respiratory depression, somnolence).

Educational objective:
Constipation is the most common side effect of opiate therapy and occurs due to the binding of μ-opioid receptors in the gastrointestinal tract, which decreases intestinal motility and inhibits ion and fluid secretion. Methylnaltrexone, a peripherally acting μ-opioid receptor antagonist that does not cross the blood-brain barrier, can alleviate opioid-induced constipation without inducing opiate-related withdrawal symptoms.

References

- Opioid-induced constipation: advances and clinical guidance.

Pharmacology	Gastrointestinal & Nutrition	Opioids
Subject	System	Topic

A 28-year-old man comes to the emergency department due to progressive abdominal pain. Although he has had mild abdominal cramps in the past, he has never before experienced anything this severe. The patient has 8-10 watery stools a day, weight loss, fatigue, and lethargy. Temperature is 38.3 C (100.9 F), blood pressure is 125/82 mm Hg, pulse is 95/min, and respirations are 14/min. The abdomen is tender to palpation without rebound or guarding. Abdominal CT scan reveals inflammatory changes affecting the ascending colon, sigmoid colon, and terminal ileum. Intestinal biopsy reveals the following:

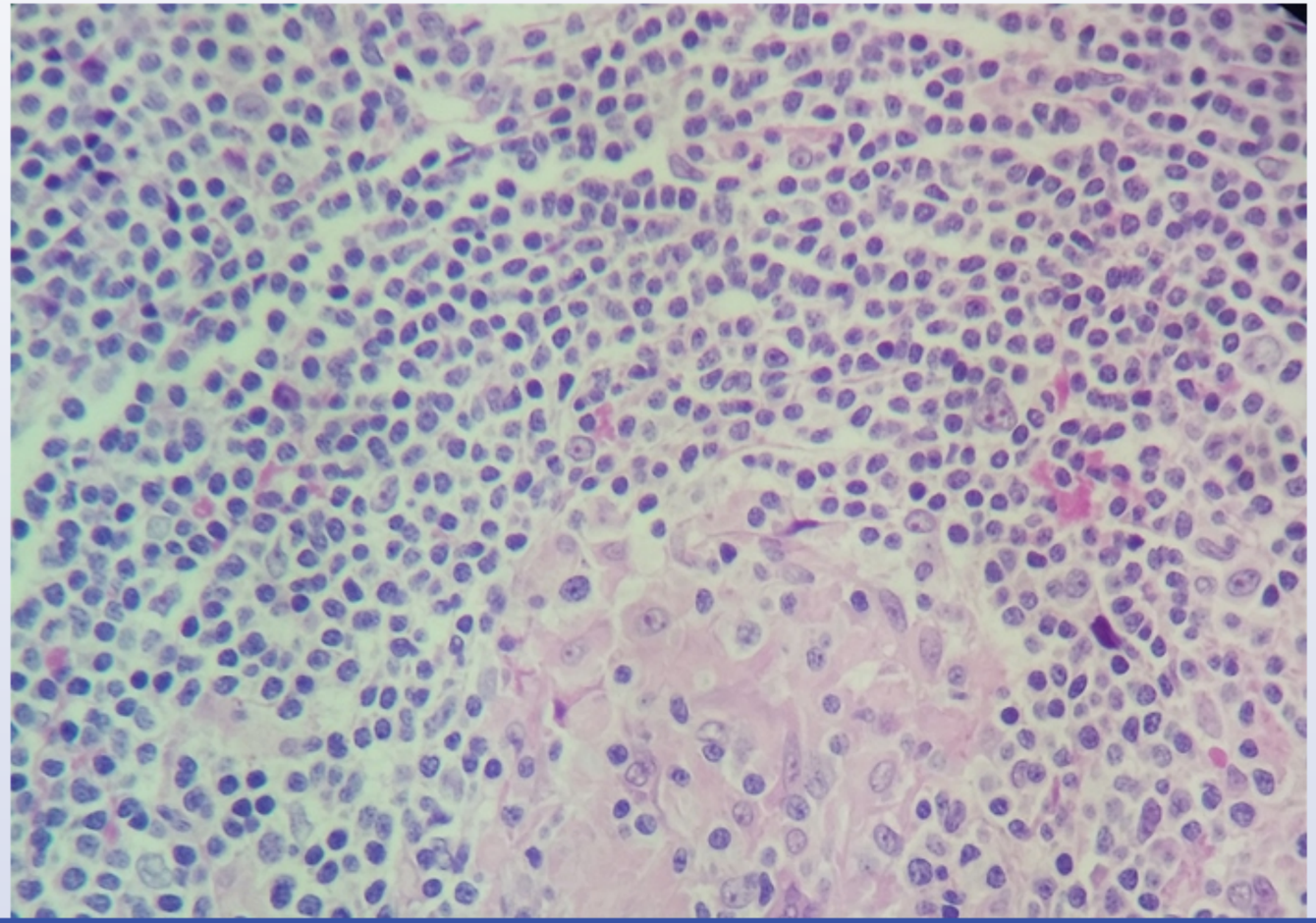

1
2
3
4
5
6
7
8
9
10
11
12
13
14
15
16
17
18
19
20
21
22
23
24
25
26
27
28
29
30
31

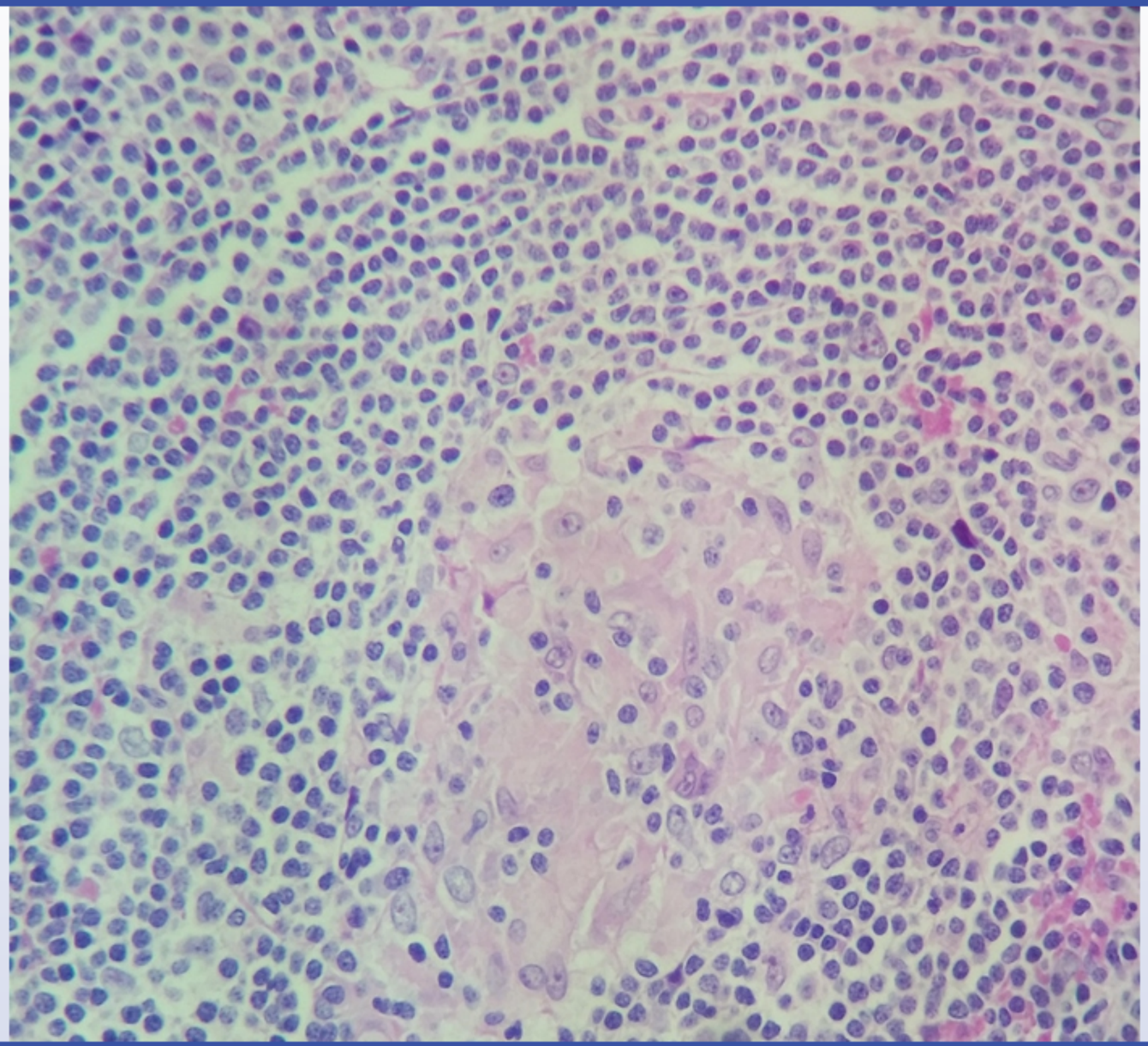

1
2
3
4
5
6
7
8
9
10
11
12
13
14
15
16
17
18
19
20
21
22
23
24
25
26
27
28
29
30
31

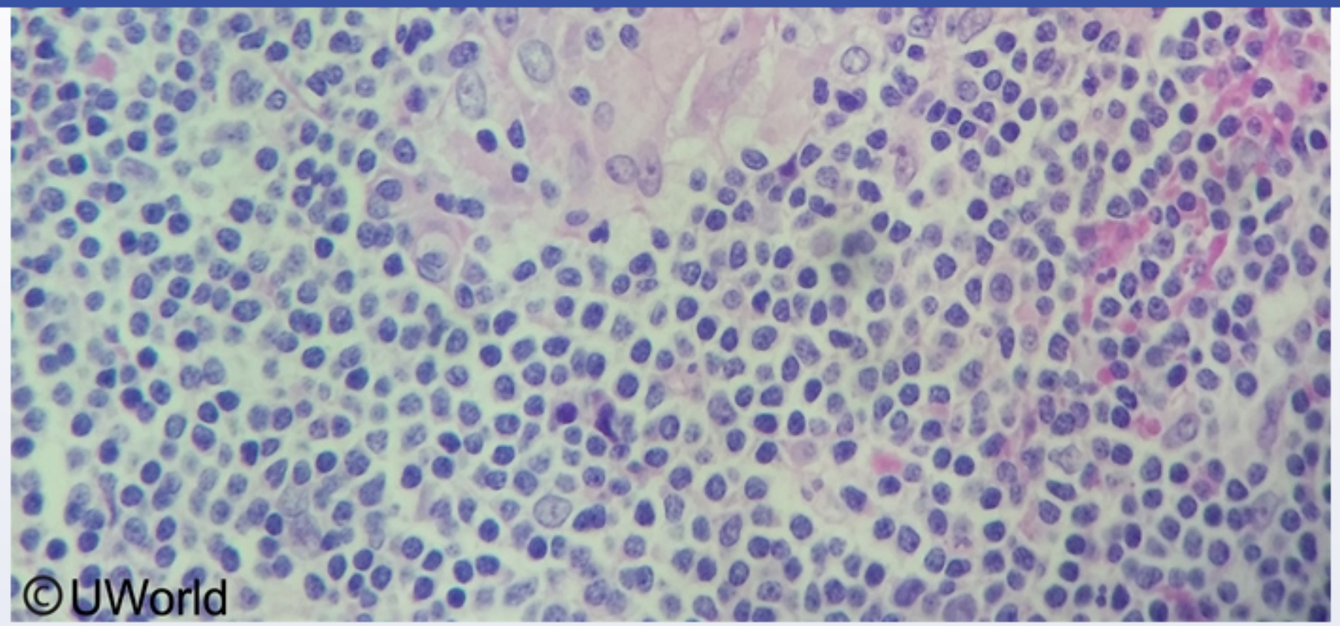

Effective treatment of this patient's condition could be achieved by targeting which of the following molecules?

- A. BCR-ABL protein tyrosine kinase
- B. CD20 lymphocyte antigen
- C. mTOR protein kinase
- D. Programmed cell death-1 protein
- E. Tumor necrosis factor-alpha

Submit

1
2
3
4
5
6
7
8
9
10
11
12
13
14
15
16
17
18
19
20
21
22
23
24
25
26
27
28
29
30
31

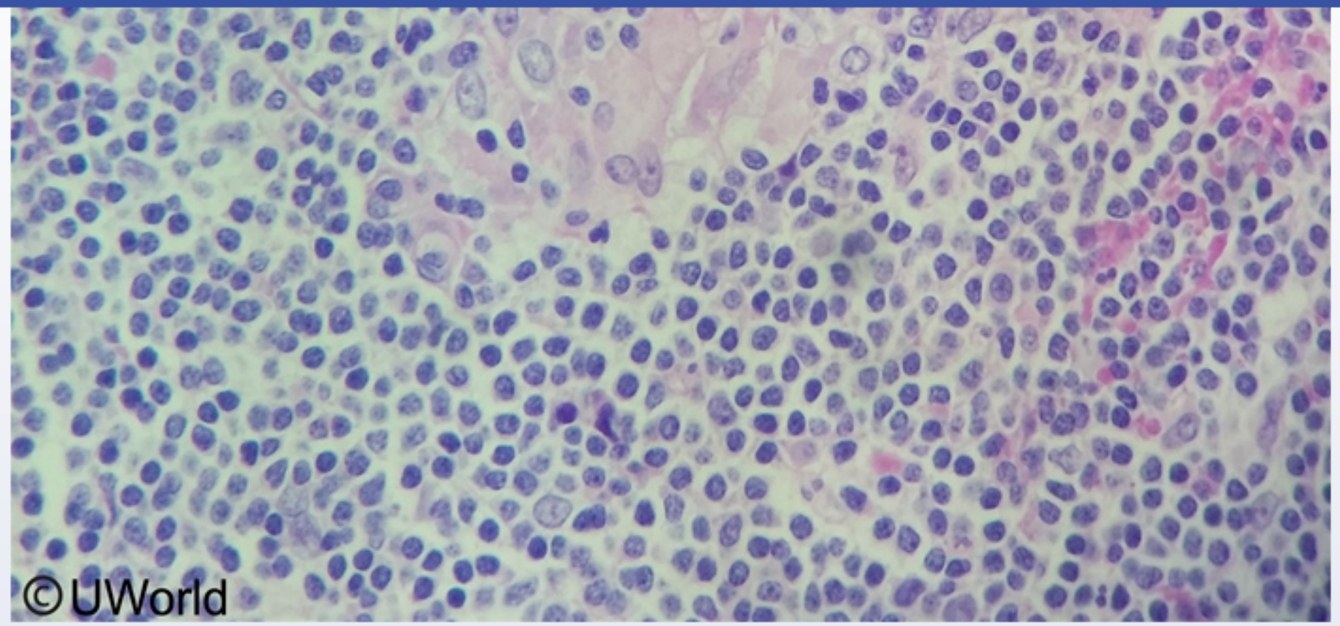

Effective treatment of this patient's condition could be achieved by targeting which of the following molecules?

A. BCR-ABL protein tyrosine kinase (3%)

B. CD20 lymphocyte antigen (9%)

C. mTOR protein kinase (6%)

D. Programmed cell death-1 protein (3%)

✓ E. Tumor necrosis factor-alpha (77%)

Omitted
Correct answer

77%
Answered correctly

09 secs
Time Spent

04/06/2020
Last Updated

Crohn disease	
Involvement	• Extending from the mouth to the anus (mostly ileum & colon) • Rectum spared • Perianal disease • Skip lesions
Microscopy	• Noncaseating granulomas
Gross findings	• Transmural inflammation • Linear mucosal ulcerations • Cobblestoning • Creeping fat
Clinical manifestations	• Diarrhea (bloody if colitis)
Intestinal complications	• Fistulae • Strictures (bowel obstruction) • Abscesses

This patient with recurrent abdominal pain, diarrhea, weight loss, and low-grade fevers has inflammatory changes of the colon and terminal ileum. In association with the characteristic intestinal biopsy findings, this presentation is consistent with **Crohn disease** (CD). CD is an inflammatory bowel disease that causes **patchy inflammation** throughout the gastrointestinal (GI) tract but spares the rectum; patients typically have segments of normal bowel interspersed with areas of disease (skip lesions).

The presence of noncaseating granulomas on intestinal biopsy is highly suggestive of CD. These lesions are characterized by the accumulation of epithelioid macrophages that fuse to form multinucleated cells surrounded by a band of lymphocytes. Other characteristic histopathologic findings in CD include inflammation involving the entire thickness of the intestinal wall (transmural inflammation), distortion of normal mucosal architecture, and Paneth cell metaplasia.

This patient with recurrent abdominal pain, diarrhea, weight loss, and low-grade fevers has inflammatory changes of the colon and terminal ileum. In association with the characteristic intestinal biopsy findings, this presentation is consistent with **Crohn disease** (CD). CD is an inflammatory bowel disease that causes **patchy inflammation** throughout the gastrointestinal (GI) tract but spares the rectum; patients typically have segments of normal bowel interspersed with areas of disease (skip lesions).

The presence of noncaseating granulomas on intestinal biopsy is highly suggestive of CD. These lesions are characterized by the accumulation of epithelioid macrophages that fuse to form multinucleated cells surrounded by a band of lymphocytes. Other characteristic histopathologic findings in CD include inflammation involving the entire thickness of the intestinal wall (transmural inflammation), distortion of normal mucosal architecture, and Paneth cell metaplasia.

Tumor necrosis factor-alpha (TNF-α), an inflammatory cytokine produced by macrophages, plays a central role in the pathogenesis of CD. It **promotes intestinal inflammation** by inducing lymphocyte proliferation, enhancing migration of neutrophils into the GI tract, and stimulating macrophage activity. Several TNF-α inhibitors (eg, infliximab, adalimumab) are used as first-line therapy in the treatment of CD.

(Choice A) Chronic myeloid leukemia (CML) occurs from a translocation between chromosomes 9 and 22, leading to creation of the BCR-ABL (fusion) protein tyrosine kinase. Imatinib, a direct inhibitor of BCR-ABL, is effective for CML but not for CD.

(Choice B) CD20 antigen is specific to B lymphocytes. Rituximab, a monoclonal antibody directed at CD20, results in B cell depletion. It is used in multiple autoimmune disorders (eg, rheumatoid arthritis) but not CD.

(Choice C) mTOR (mammalian target of rapamycin) is a stimulator of cell growth and proliferation. Sirolimus, an mTOR inhibitor, is used in patients with solid organ transplants to prevent allograft rejection.

(Choice D) Programmed cell death-1 (PD-1) is an immune checkpoint molecule that downregulates the immune response. PD-1 inhibitors (eg, nivolumab, pembrolizumab) are cancer immunotherapy drugs used to stimulate the immune response against malignant cells.

Educational objective:
Crohn disease is an inflammatory bowel disorder that causes patchy inflammation throughout the gastrointestinal tract. Characteristic histopathologic findings include noncaseating granulomas, transmural inflammation, and Paneth cell metaplasia. Tumor necrosis factor-alpha (TNF-α), a cytokine produced by macrophages, plays a central role in the pathogenesis of CD; anti–TNF-α agents (eg, infliximab, adalimumab) are often used as first-line therapy.

architecture, and Paneth cell metaplasia.

Tumor necrosis factor-alpha (TNF-α), an inflammatory cytokine produced by macrophages, plays a central role in the pathogenesis of CD. It **promotes intestinal inflammation** by inducing lymphocyte proliferation, enhancing migration of neutrophils into the GI tract, and stimulating macrophage activity. Several TNF-α inhibitors (eg, infliximab, adalimumab) are used as first-line therapy in the treatment of CD.

(Choice A) Chronic myeloid leukemia (CML) occurs from a translocation between chromosomes 9 and 22, leading to creation of the BCR-ABL (fusion) protein tyrosine kinase. Imatinib, a direct inhibitor of BCR-ABL, is effective for CML but not for CD.

(Choice B) CD20 antigen is specific to B lymphocytes. Rituximab, a monoclonal antibody directed at CD20, results in B cell depletion. It is used in multiple autoimmune disorders (eg, rheumatoid arthritis) but not CD.

(Choice C) mTOR (mammalian target of rapamycin) is a stimulator of cell growth and proliferation. Sirolimus, an mTOR inhibitor, is used in patients with solid organ transplants to prevent allograft rejection.

(Choice D) Programmed cell death-1 (PD-1) is an immune checkpoint molecule that downregulates the immune response. PD-1 inhibitors (eg, nivolumab, pembrolizumab) are cancer immunotherapy drugs used to stimulate the immune response against malignant cells.

Educational objective:
Crohn disease is an inflammatory bowel disorder that causes patchy inflammation throughout the gastrointestinal tract. Characteristic histopathologic findings include noncaseating granulomas, transmural inflammation, and Paneth cell metaplasia. Tumor necrosis factor-alpha (TNF-α), a cytokine produced by macrophages, plays a central role in the pathogenesis of CD; anti–TNF-α agents (eg, infliximab, adalimumab) are often used as first-line therapy.

References

- Role of cytokines in the pathogenesis of inflammatory bowel disease.

Pharmacology	Gastrointestinal & Nutrition	Inflammatory bowel disease
Subject	System	Topic

Copyright © UWorld. All rights reserved.

1
2
3
4
5
6
7
8
9
10
11
12
13
14
15
16
17
18
19
20
21
22
23
24
25
26
27
28
29
30
31

- Creeping fat

Exhibit Display

Crohn's disease

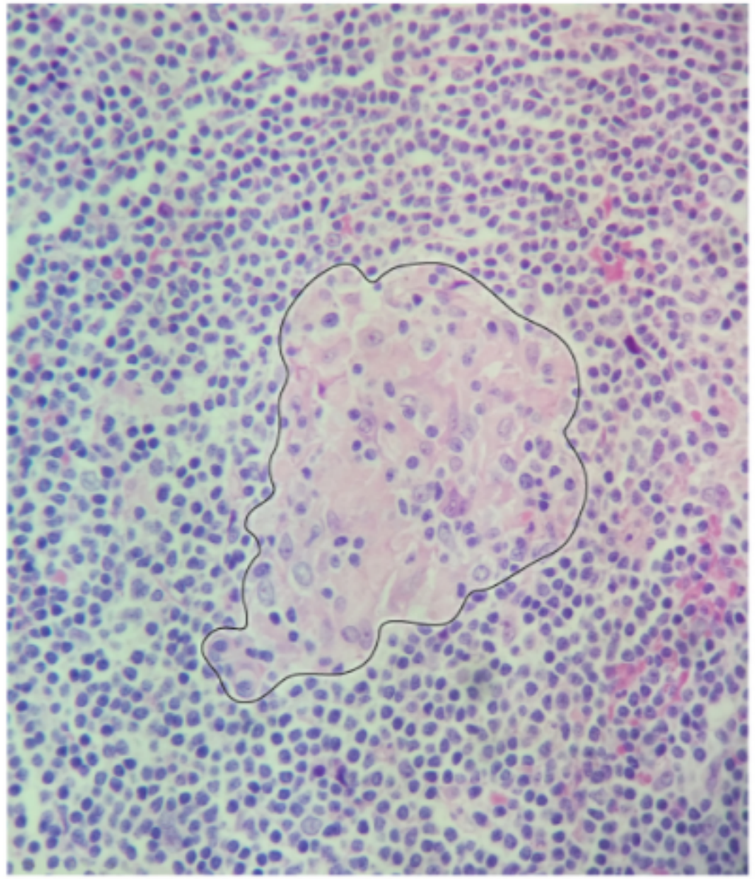

©UWorld

Zoom In Zoom Out Reset Add To Flash Card

1
2
3
4
5
6
7
8
9
10
11
12
13
14
15
16
17
18
19
20
21
22
23
24
25
26
27
28
29
30
31

A 64-year-old woman is diagnosed with rheumatoid arthritis after coming to the office with symmetrical joint pain, swelling, and morning stiffness. The patient has a remote history of peptic ulcer disease and was treated with multidrug therapy for *Helicobacter pylori* eradication; a follow-up *H pylori* stool antigen test was negative and she had no recurrent symptoms. The patient is started on methotrexate and high-dose ibuprofen therapy. In addition, daily lansoprazole is prescribed for protection against the adverse gastrointestinal effects of ibuprofen. Three months later, joint symptoms were greatly improved. Ibuprofen and lansoprazole were discontinued. However, 2 weeks later, she begins experiencing heartburn after meals. Which of the following is the most likely cause of this patient's new gastrointestinal symptoms?

A. Downregulation of vagal stimulation

B. Gastrin-mediated rebound acid hypersecretion

C. Increased prostaglandin production after ibuprofen discontinuation

D. Recolonization with *Helicobacter pylori*

E. Upregulation of somatostatin receptors

Submit

A 64-year-old woman is diagnosed with rheumatoid arthritis after coming to the office with symmetrical joint pain, swelling, and morning stiffness. The patient has a remote history of peptic ulcer disease and was treated with multidrug therapy for *Helicobacter pylori* eradication; a follow-up *H pylori* stool antigen test was negative and she had no recurrent symptoms. The patient is started on methotrexate and high-dose ibuprofen therapy. In addition, daily lansoprazole is prescribed for protection against the adverse gastrointestinal effects of ibuprofen. Three months later, joint symptoms were greatly improved. Ibuprofen and lansoprazole were discontinued. However, 2 weeks later, she begins experiencing heartburn after meals. Which of the following is the most likely cause of this patient's new gastrointestinal symptoms?

- A. Downregulation of vagal stimulation (1%)
- ✓ B. Gastrin-mediated rebound acid hypersecretion (85%)
- C. Increased prostaglandin production after ibuprofen discontinuation (6%)
- D. Recolonization with *Helicobacter pylori* (4%)
- E. Upregulation of somatostatin receptors (1%)

Omitted
Correct answer
B

85%
Answered correctly

02 secs
Time Spent

07/01/2020
Last Updated

Explanation

Parietal cell acid secretion

Vagus nerve

1
2
3
4
5
6
7
8
9
10
11
12
13
14
15
16
17
18
19
20
21
22
23
24
25
26
27
28
29
30
31

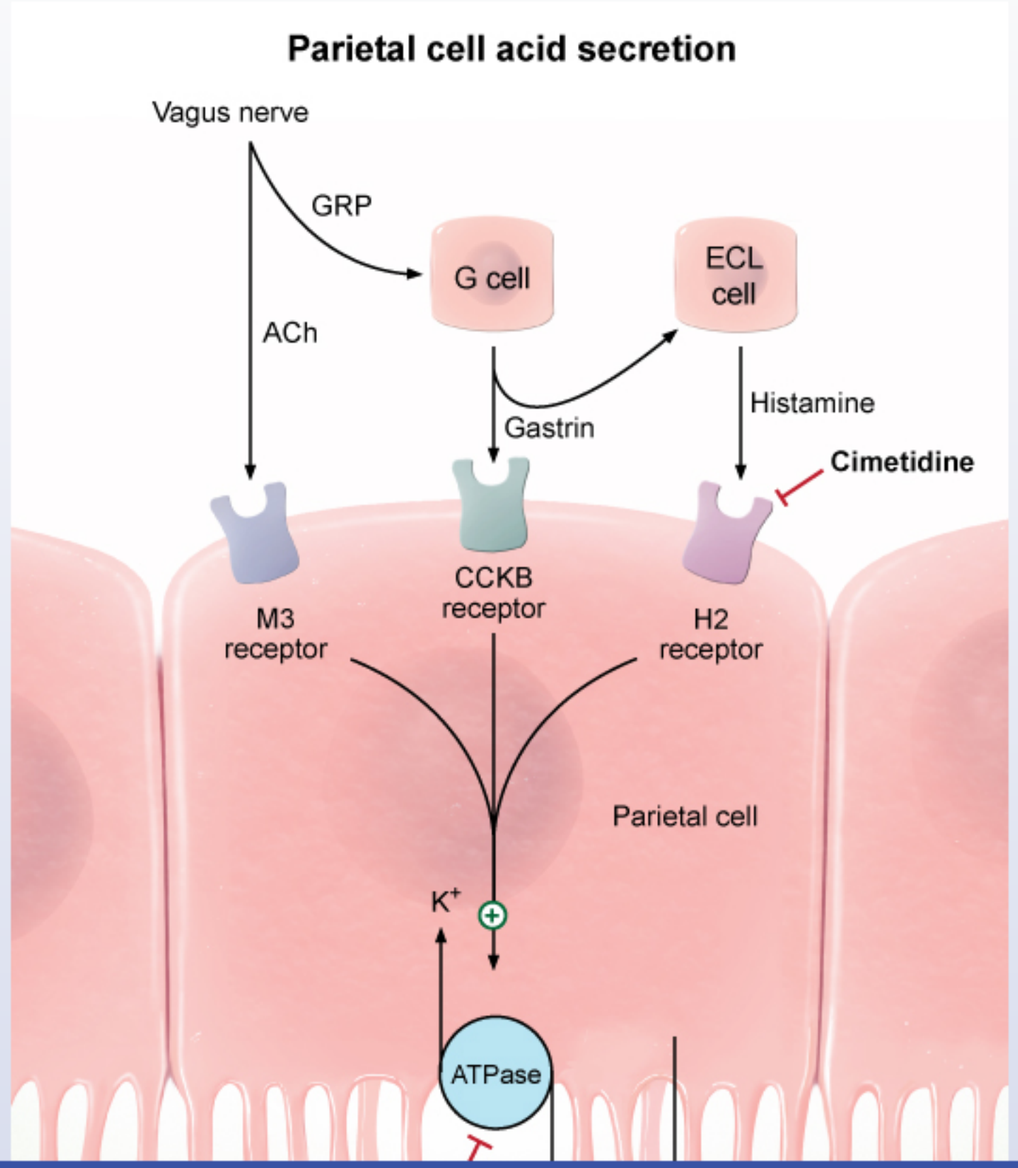

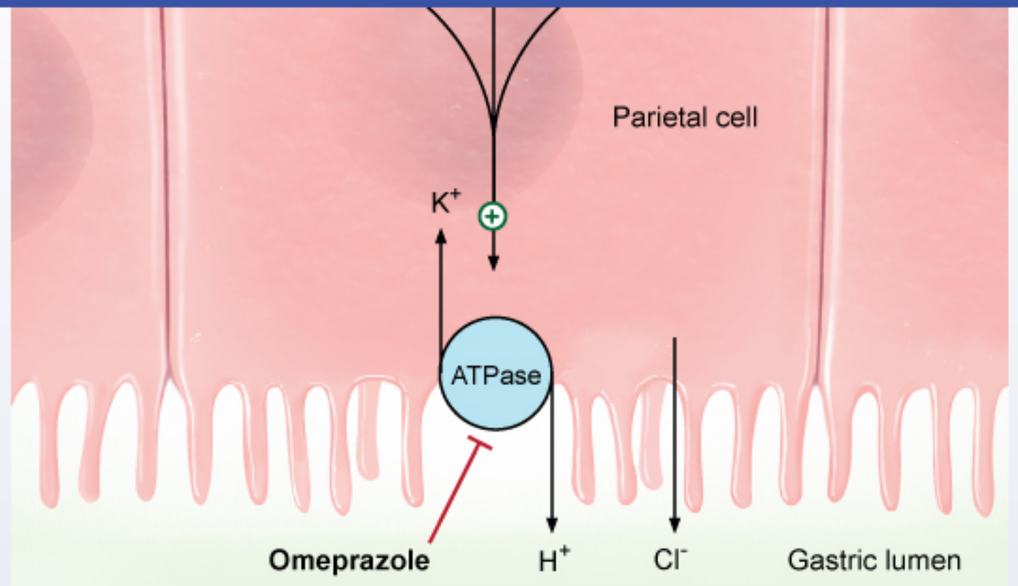

ACh = acetylcholine; **CCKB** = cholecystokinin B; **ECL** = enterochromaffin like;
GRP = gastrin-releasing peptide; **M3** = muscarinic.
©UWorld

Release of gastrin, a hormone produced by G cells in the gastric antrum, is stimulated by dietary protein intake, gastrin-releasing peptide (released in response to vagal stimuli), and increased gastric pH. Gastrin induces acid production directly by binding parietal cells and indirectly by binding enterochromaffin-like (ECL) cells and inducing histamine release.

Proton pump inhibitors (PPIs) (eg, omeprazole, lansoprazole) inhibit the hydrogen-potassium-ATPase pump and **decrease hydrochloric acid** production regardless of stimuli. The resultant increase in gastric pH leads to **increased gastrin** formation, which induces hypertrophy of the ECL and parietal cells. **Withdrawal** of the PPI results in overstimulation of the parietal cells with hyperfunctioning of the unblocked ATPase, leading to **rebound gastric acid hypersecretion** and reflux symptoms. PPIs can be slowly tapered to help prevent this adverse effect.

(Choice A) Acetylcholine (released with vagal stimulation) binds to parietal cell muscarinic (M3) receptors and promotes the secretion of hydrochloric acid. Downregulation of vagal tone would likely relieve, rather than cause, the patient's symptoms.

(Choice C) Prostaglandins decrease acid production by inhibiting the downstream messenger of histamine and increases bicarbonate formation

Release of gastrin, a hormone produced by G cells in the gastric antrum, is stimulated by dietary protein intake, gastrin-releasing peptide (released in response to vagal stimuli), and increased gastric pH. Gastrin induces acid production directly by binding parietal cells and indirectly by binding enterochromaffin-like (ECL) cells and inducing histamine release.

Proton pump inhibitors (PPIs) (eg, omeprazole, lansoprazole) inhibit the hydrogen-potassium-ATPase pump and **decrease hydrochloric acid** production regardless of stimuli. The resultant increase in gastric pH leads to **increased gastrin** formation, which induces hypertrophy of the ECL and parietal cells. **Withdrawal** of the PPI results in overstimulation of the parietal cells with hyperfunctioning of the unblocked ATPase, leading to **rebound gastric acid hypersecretion** and reflux symptoms. PPIs can be slowly tapered to help prevent this adverse effect.

(Choice A) Acetylcholine (released with vagal stimulation) binds to parietal cell muscarinic (M3) receptors and promotes the secretion of hydrochloric acid. Downregulation of vagal tone would likely relieve, rather than cause, the patient's symptoms.

(Choice C) Prostaglandins decrease acid production by inhibiting the downstream messenger of histamine and increases bicarbonate formation from gastric epithelial cells. Nonsteroidal anti-inflammatory drugs (eg ibuprofen) inhibit prostaglandin formation and increase the risk of gastritis and peptic ulcer formation. Increased prostaglandin formation after drug withdrawal would be protective against gastritis.

(Choice D) Chronic *Helicobacter pylori* infection causes atrophic gastritis with parietal cell destruction. The effects of hypergastrinemia are masked in these patients due to the inability of the remaining parietal cells to create large volumes of acid. Reinfection is very rare, and the correlation with PPI withdrawal makes rebound hypersecretion more likely.

(Choice E) Somatostatin inhibits histamine and gastrin release; upregulation would lead to reduced gastric acid formation.

Educational objective:
Elevated gastric pH stimulates secretion of gastrin, a polypeptide hormone that increases gastric acid production. Proton pump inhibitors block gastric acid production by parietal cells; the resultant increase in pH leads to hypergastrinemia, which can cause rebound hypersecretion of gastric acid when the drug is withdrawn.

Pharmacology	Gastrointestinal & Nutrition	Peptic ulcer disease
Subject	System	Topic

Copyright © UWorld. All rights reserved.

To assess bioavailability of a drug, investigators administered it intravenously to a volunteer and measured the plasma concentration of the drug over time. The investigators subsequently administered the same dose of the drug orally to the same person and similarly measured the plasma concentration of the drug over time. The curves were plotted on the graph below.

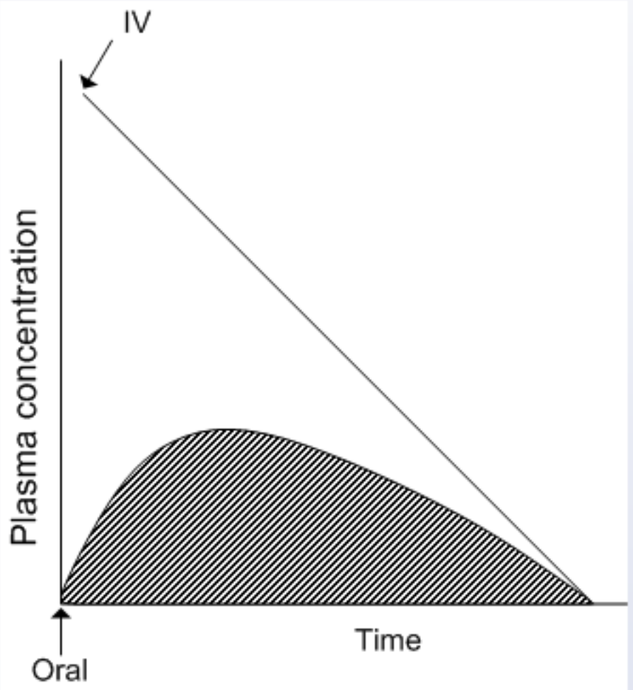

Which of the following is the best determinant of oral bioavailability of the drug in this person?

A. Slope of the IV curve divided by the slope of the oral curve

B. Area under the oral curve

C. Maximal concentration at the peak of the oral curve

D. Rate of elimination for the IV curve divided by rate of elimination for the oral curve

1
2
3
4
5
6
7
8
9
10
11
12
13
14
15
16
17
18
19
20
21
22
23
24
25
26
27
28
29
30
31

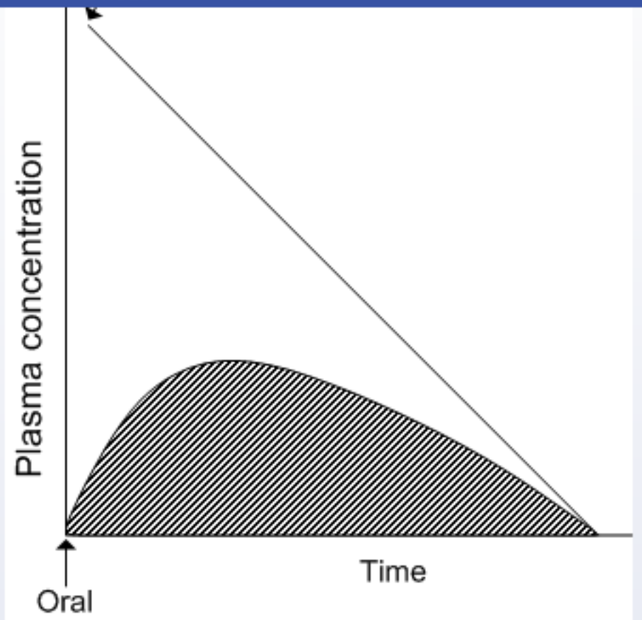

Which of the following is the best determinant of oral bioavailability of the drug in this person?

A. Slope of the IV curve divided by the slope of the oral curve

B. Area under the oral curve

C. Maximal concentration at the peak of the oral curve

D. Rate of elimination for the IV curve divided by rate of elimination for the oral curve

E. Area under the oral curve divided by area under the IV curve

Submit

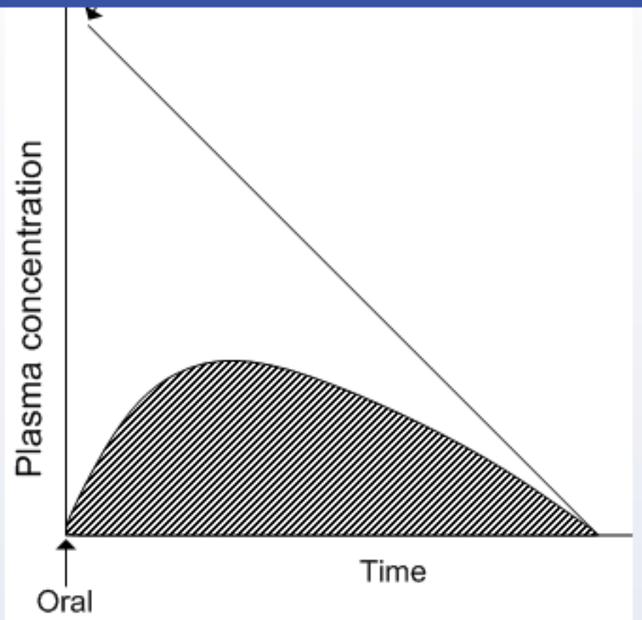

Which of the following is the best determinant of oral bioavailability of the drug in this person?

A. Slope of the IV curve divided by the slope of the oral curve (3%)

B. Area under the oral curve (33%)

C. Maximal concentration at the peak of the oral curve (10%)

D. Rate of elimination for the IV curve divided by rate of elimination for the oral curve (6%)

✓ E. Area under the oral curve divided by area under the IV curve (47%)

Omitted
Correct answer

47%
Answered correctly

05 secs
Time Spent

02/03/2020
Last Updated

Bioavailability refers to the fraction of administered drug that reaches the systemic circulation in a chemically unchanged form. In mathematical calculations, bioavailability is represented by the letter F, which is equal to the percent bioavailability divided by 100. Generally, an intravenously administered drug has 100% bioavailability (F = 1). For other modes of drug administration, such as oral, intramuscular, inhalational, or topical, the bioavailability is usually less than 100%, so F is typically less than 1.

The bioavailability of a drug after non-intravenous administration can only be determined after conducting a study of the pharmacokinetics of the drug. This study must plot the plasma drug concentration as a function of time for a given dose of drug administered by both the intravenous route and the other route being studied (i.e. PO, SQ, IM, PR, inhalation, SL, transdermal). Oral bioavailability (F) of the drug in question can then be calculated by dividing the area under the curve (AUC) of oral administration by the AUC of intravenous administration, assuming that the dose administered by each route is equal. If the administered doses are not equivalent, the calculation may be carried out as follows:

F = (area under oral curve x IV dose) / (area under IV curve x oral dose)

In the case of oral administration, bioavailability is affected by gastric acidity and motility, the capability of the drug to be absorbed by the gut, the presence of material such as food or other drugs in the gut, and first-pass metabolism by the liver.

(Choice A) While dividing the slope of the IV curve by the slope of the oral curve would produce a fraction, that fraction would be greater than one, which is not a sensible answer to this question as the oral bioavailability can never be higher than the IV bioavailability.

(Choice B) The area under the oral curve simply represents the total amount of drug that was absorbed by the body and made available in the systemic circulation from the time of administration to the time of complete elimination.

(Choice C) The maximal concentration at the peak of the oral curve represents the peak plasma level of drug after administration of a given dose. This peak concentration is dose-dependent and has no bearing on bioavailability.

(Choice D) The rate of elimination for the IV curve or for the oral curve has to do with the mode of elimination used by the body to eliminate the drug (zero-order kinetics, first-order kinetics). If a constant fraction of drug is eliminated per unit time based on plasma concentration, then first order elimination is occurring. If a constant amount of drug is eliminated for every unit time regardless of plasma concentration, then zero-order kinetics is occurring. However, elimination is not what the question is asking about, since bioavailability is dependent on the process of absorption.

F = (area under oral curve x IV dose) / (area under IV curve x oral dose)

In the case of oral administration, bioavailability is affected by gastric acidity and motility, the capability of the drug to be absorbed by the gut, the presence of material such as food or other drugs in the gut, and first-pass metabolism by the liver.

(Choice A) While dividing the slope of the IV curve by the slope of the oral curve would produce a fraction, that fraction would be greater than one, which is not a sensible answer to this question as the oral bioavailability can never be higher than the IV bioavailability.

(Choice B) The area under the oral curve simply represents the total amount of drug that was absorbed by the body and made available in the systemic circulation from the time of administration to the time of complete elimination.

(Choice C) The maximal concentration at the peak of the oral curve represents the peak plasma level of drug after administration of a given dose. This peak concentration is dose-dependent and has no bearing on bioavailability.

(Choice D) The rate of elimination for the IV curve or for the oral curve has to do with the mode of elimination used by the body to eliminate the drug (zero-order kinetics, first-order kinetics). If a constant fraction of drug is eliminated per unit time based on plasma concentration, then first order elimination is occurring. If a constant amount of drug is eliminated for every unit time regardless of plasma concentration, then zero-order kinetics is occurring. However, elimination is not what the question is asking about, since bioavailability is dependent on the process of absorption.

Educational Objective:
Bioavailability refers to the fraction of administered drug that reaches the systemic circulation in a chemically unchanged form. Bioavailability for a drug administered by a non-intravenous route is always less than 1. It can be determined by examining a graph of plasma concentration versus time and then applying the formula:

F = (AUC oral x dose IV) / (AUC IV x dose oral)

Pharmacology	Gastrointestinal & Nutrition	Route of administration & bioavailability
Subject	System	Topic

Copyright © UWorld. All rights reserved.

A 64-year-old woman comes to the emergency department due to intractable nausea and vomiting. She has not been able to keep anything down and feels weak and tired. The patient has had no diarrhea, constipation, or abdominal pain. She was diagnosed with breast cancer 4 weeks ago and received her first cycle of chemotherapy 1 week ago. Vital signs are within normal limits. Mucous membranes are dry. Cardiopulmonary examination is normal. Bowel sounds are normal. Which of the following agents would be most helpful in treating this patient's symptoms?

A. Histamine H_1 blocker

B. Motilin receptor agonist

C. Mu opioid receptor agonist

D. Muscarinic M_1 receptor antagonist

E. Serotonin 5-HT_3 receptor antagonist

Submit

A 64-year-old woman comes to the emergency department due to intractable nausea and vomiting. She has not been able to keep anything down and feels weak and tired. The patient has had no diarrhea, constipation, or abdominal pain. She was diagnosed with breast cancer 4 weeks ago and received her first cycle of chemotherapy 1 week ago. Vital signs are within normal limits. Mucous membranes are dry. Cardiopulmonary examination is normal. Bowel sounds are normal. Which of the following agents would be most helpful in treating this patient's symptoms?

A. Histamine H_1 blocker

B. Motilin receptor agonist

C. Mu opioid receptor agonist

D. Muscarinic M_1 receptor antagonist

E. Serotonin 5-HT_3 receptor antagonist

Submit

A 64-year-old woman comes to the emergency department due to intractable nausea and vomiting. She has not been able to keep anything down and feels weak and tired. The patient has had no diarrhea, constipation, or abdominal pain. She was diagnosed with breast cancer 4 weeks ago and received her first cycle of chemotherapy 1 week ago. Vital signs are within normal limits. Mucous membranes are dry. Cardiopulmonary examination is normal. Bowel sounds are normal. Which of the following agents would be most helpful in treating this patient's symptoms?

A. Histamine H_1 blocker (3%)

B. Motilin receptor agonist (2%)

C. Mu opioid receptor agonist (5%)

D. Muscarinic M_1 receptor antagonist (6%)

✓ E. Serotonin 5-HT_3 receptor antagonist (82%)

Omitted
Correct answer
E

82%
Answered correctly

03 secs
Time Spent

04/13/2020
Last Updated

Explanation

Characteristics of antiemetic drugs		
Drug class	**Examples**	**Clinical uses**
Antimuscarinics	• Scopolamine	

1
2
3
4
5
6
7
8
9
10
11
12
13
14
15
16
17
18
19
20
21
22
23
24
25
26
27
28
29
30
31

Characteristics of antiemetic drugs

Drug class	Examples	Clinical uses
Antimuscarinics (anticholinergics)	• Scopolamine	Motion sickness Hyperemesis gravidarum (promethazine)
Antihistamines	• Diphenhydramine • Meclizine • Promethazine	
Dopamine receptor antagonists	• Prochlorperazine • Metoclopramide	Chemotherapy-induced emesis
Serotonin (5-HT_3) receptor antagonists	• Ondansetron • Granisetron	
Neurokinin 1 (NK1) receptor antagonists	• Aprepitant • Fosaprepitant	

©UWorld

The vomiting reflex can be activated by either humoral or neuronal stimuli. The **area postrema** in the fourth ventricle has a **chemoreceptor trigger zone** that can respond to many neurotransmitters, drugs, or toxins. The **nucleus tractus solitarius** (NTS) in the medulla receives information from the area postrema, gastrointestinal (GI) tract via the vagus nerve, vestibular system, and central nervous system (eg, meninges, hypothalamus). Neurons from the NTS project to other medullary nuclei and coordinate the vomiting process. The 5 major receptors involved in

©UWorld

The vomiting reflex can be activated by either humoral or neuronal stimuli. The **area postrema** in the fourth ventricle has a **chemoreceptor trigger zone** that can respond to many neurotransmitters, drugs, or toxins. The **nucleus tractus solitarius** (NTS) in the medulla receives information from the area postrema, gastrointestinal (GI) tract via the vagus nerve, vestibular system, and central nervous system (eg, meninges, hypothalamus). Neurons from the NTS project to other medullary nuclei and coordinate the vomiting process. The 5 major receptors involved in stimulating the vomiting reflex in the area postrema and adjacent vomiting center nuclei are M_1 muscarinic, D_2 dopaminergic, H_1 histaminic, 5-HT_3 serotonergic, and neurokinin 1 (NK1) receptors.

5-HT_3 receptor antagonists (eg, ondansetron, granisetron, dolasetron) are highly effective in preventing **chemotherapy-induced vomiting**. These agents act by 2 primary mechanisms: blocking **vagus**-mediated nausea and vomiting (from the GI tract stimuli) and blocking central **serotonin** receptors in the area postrema and the NTS. Other agents useful for chemotherapy-induced vomiting include NK1 **receptor antagonists** (eg, aprepitant), which inhibit substance P and help prevent both acute vomiting and delayed emesis; and dopamine receptor antagonists (eg, metoclopramide), which are associated with drowsiness and dystonic reactions.

(Choices A and D) Histamine blockers and antimuscarinic/anticholinergic agents are most helpful for vestibular nausea and vomiting.

(Choice B) Motilin regulates interdigestive migrating contractions. Erythromycin is a motilin receptor agonist used for gastroparesis.

(Choice C) Mu opioid receptor agonists (eg, morphine) are useful for cancer-related pain control but often have side effects such as nausea and vomiting.

Educational objective:
Ondansetron inhibits serotonin (5-HT_3) receptors and is used primarily to treat nausea and vomiting following chemotherapy. 5-HT_3 receptors are located peripherally in the presynaptic nerve terminals of the vagus nerve in the gastrointestinal tract. These receptors are also present centrally in the chemoreceptor trigger zone and the solitary nucleus and tract.

Pharmacology	Gastrointestinal & Nutrition	Nausea and vomiting
Subject	System	Topic

Copyright © UWorld. All rights reserved.

Exhibit Display

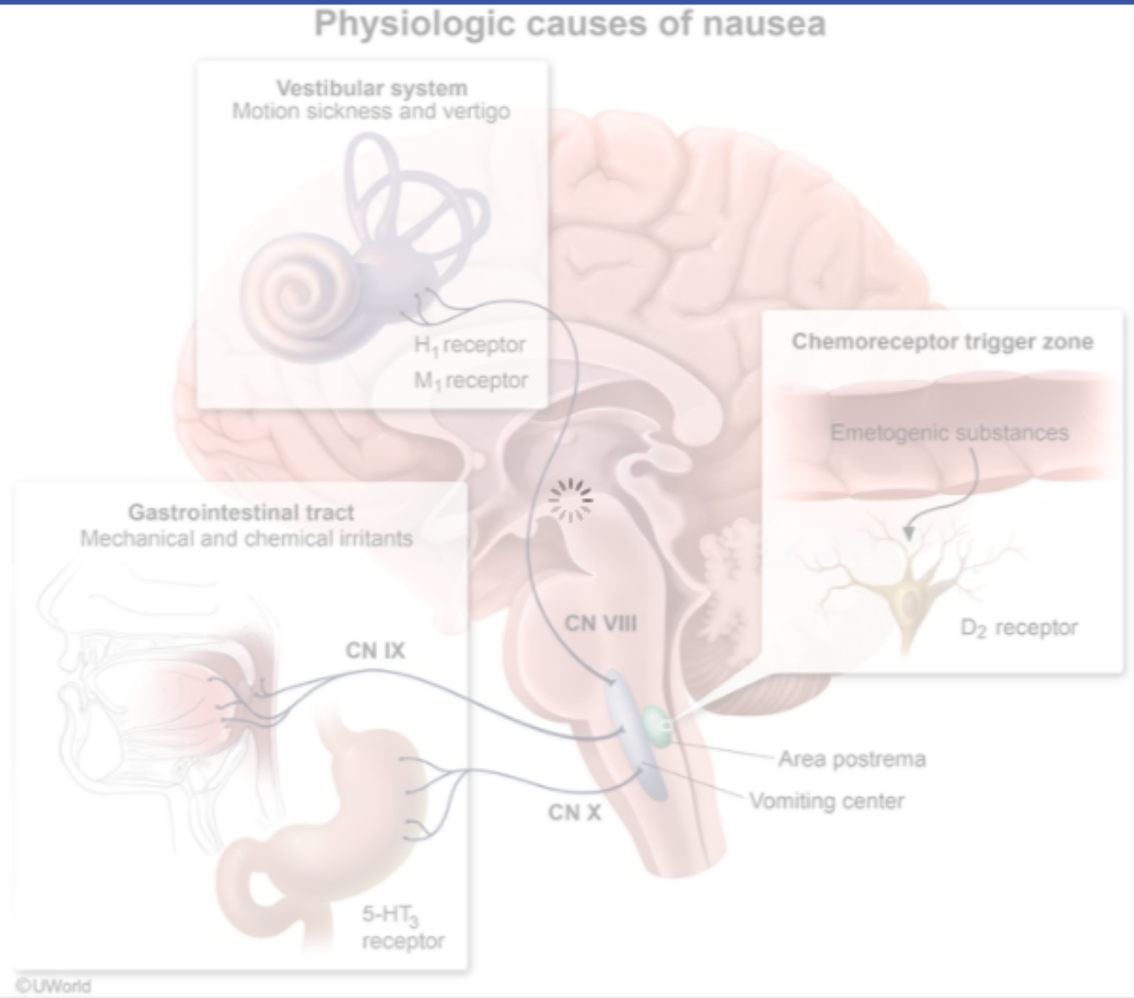

Zoom In | Zoom Out | Reset | Add To New Card | Existing Card

Copyright © UWorld. All rights reserved.

1
2
3
4
5
6
7
8
9
10
11
12
13
14
15
16
17
18
19
20
21
22
23
24
25
26
27
28
29
30
31

A 42-year-old woman comes to the office due to frequent episodes of burning in her chest and small amounts of regurgitation after meals and at nighttime. Medical history includes hypertension. Vital signs are within normal limits. BMI is 30 kg/m^2. There is no abdominal tenderness and the remainder of the physical examination is normal. The patient shows the clinician an over-the-counter antacid that she has been taking to relieve her symptoms. The preparation contains a combination of magnesium and aluminum hydroxide. Which of the following is the most likely rationale for combining both mineral salts in this antacid preparation?

A. Improve systemic absorption

B. Minimize drug interactions

C. Prevent rebound acid secretion

D. Reduce adverse effects

E. Reduce the risk of alkalosis and renal failure

Submit

A 42-year-old woman comes to the office due to frequent episodes of burning in her chest and small amounts of regurgitation after meals and at nighttime. Medical history includes hypertension. Vital signs are within normal limits. BMI is 30 kg/m^2. There is no abdominal tenderness and the remainder of the physical examination is normal. The patient shows the clinician an over-the-counter antacid that she has been taking to relieve her symptoms. The preparation contains a combination of magnesium and aluminum hydroxide. Which of the following is the most likely rationale for combining both mineral salts in this antacid preparation?

- A. Improve systemic absorption (9%)
- B. Minimize drug interactions (3%)
- C. Prevent rebound acid secretion (19%)
- ✓ D. Reduce adverse effects (55%)
- E. Reduce the risk of alkalosis and renal failure (12%)

Omitted
Correct answer
D

55%
Answered correctly

02 secs
Time Spent

02/19/2020
Last Updated

Explanation

Magnesium salts (eg, magnesium trisilicate, magnesium hydroxide) and aluminum hydroxide are **weak alkali mineral salts**. They temporarily **increase the gastric pH** by neutralizing hydrochloric acid, helping to **relieve gastroesophageal reflux** symptoms.

Aluminum hydroxide has a tendency to cause **constipation** due to interactions with intestinal secretions that form insoluble salts. In contrast, **magnesium** salts cause osmotic **diarrhea**. Therefore, the two medications are combined to offset the adverse effects of the individual medications. Patients with reflux symptoms and chronic constipation may benefit from magnesium salt monotherapy, whereas aluminum

Explanation

Magnesium salts (eg, magnesium trisilicate, magnesium hydroxide) and aluminum hydroxide are **weak alkali mineral salts**. They temporarily **increase the gastric pH** by neutralizing hydrochloric acid, helping to **relieve gastroesophageal reflux** symptoms.

Aluminum hydroxide has a tendency to cause **constipation** due to interactions with intestinal secretions that form insoluble salts. In contrast, **magnesium** salts cause osmotic **diarrhea**. Therefore, the two medications are combined to offset the adverse effects of the individual medications. Patients with reflux symptoms and chronic constipation may benefit from magnesium salt monotherapy, whereas aluminum hydroxide monotherapy may be of value in patients with chronic diarrhea.

(Choice A) Aluminum, when absorbed in large doses, causes osteomalacia, bone pain, hypercalcemia, and dementia. Aluminum absorption in the gastrointestinal tract is minimal from the salt form, and toxicity tends to occur in patients with chronic kidney disease that limits renal excretion. Combination therapy does not alter systemic absorption.

(Choice B) Drug interactions are common with antacid medications, largely due to pH-related changes in protein binding, absorption, or elimination of the drugs. Combining multiple alkalinizing agents would not minimize their effects on other drugs.

(Choice C) Rebound acid hypersecretion can occur with calcium carbonate, magnesium hydroxide, aluminum hydroxide, and proton pump inhibitors. This is likely due to increased gastrin release as a result of gastric alkalinization or (in the case of calcium salts) direct ionic stimulation.

(Choice E) Milk-alkali syndrome is caused by excessive use of calcium carbonate antacids and is characterized by hypercalcemia, alkalosis, and renal dysfunction. Kidney injury occurs due to both hypercalcemia-induced renal vasoconstriction and calcium-induced diuresis. The resultant volume depletion, decreased glomerular filtration rate, and alkali intake lead to a metabolic alkalosis. However, severe alkalosis can occur with all antacids, and the combination of magnesium and aluminum would not decrease this risk.

Educational objective:
Magnesium salts and aluminum hydroxide are basic mineral salts used to neutralize gastric acid and relieve gastroesophageal reflux symptoms. Side effects include diarrhea and constipation, respectively. Therefore, these medications are often combined to offset the adverse effects of the individual medications.

Pharmacology | Gastrointestinal & Nutrition | Gastroesophageal reflux disease

increase the gastric pH by neutralizing hydrochloric acid, helping to **relieve gastroesophageal reflux** symptoms.

Aluminum hydroxide has a tendency to cause **constipation** due to interactions with intestinal secretions that form insoluble salts. In contrast, **magnesium** salts cause osmotic **diarrhea**. Therefore, the two medications are combined to offset the adverse effects of the individual medications. Patients with reflux symptoms and chronic constipation may benefit from magnesium salt monotherapy, whereas aluminum hydroxide monotherapy may be of value in patients with chronic diarrhea.

(Choice A) Aluminum, when absorbed in large doses, causes osteomalacia, bone pain, hypercalcemia, and dementia. Aluminum absorption in the gastrointestinal tract is minimal from the salt form, and toxicity tends to occur in patients with chronic kidney disease that limits renal excretion. Combination therapy does not alter systemic absorption.

(Choice B) Drug interactions are common with antacid medications, largely due to pH-related changes in protein binding, absorption, or elimination of the drugs. Combining multiple alkalinizing agents would not minimize their effects on other drugs.

(Choice C) Rebound acid hypersecretion can occur with calcium carbonate, magnesium hydroxide, aluminum hydroxide, and proton pump inhibitors. This is likely due to increased gastrin release as a result of gastric alkalinization or (in the case of calcium salts) direct ionic stimulation.

(Choice E) Milk-alkali syndrome is caused by excessive use of calcium carbonate antacids and is characterized by hypercalcemia, alkalosis, and renal dysfunction. Kidney injury occurs due to both hypercalcemia-induced renal vasoconstriction and calcium-induced diuresis. The resultant volume depletion, decreased glomerular filtration rate, and alkali intake lead to a metabolic alkalosis. However, severe alkalosis can occur with all antacids, and the combination of magnesium and aluminum would not decrease this risk.

Educational objective:
Magnesium salts and aluminum hydroxide are basic mineral salts used to neutralize gastric acid and relieve gastroesophageal reflux symptoms. Side effects include diarrhea and constipation, respectively. Therefore, these medications are often combined to offset the adverse effects of the individual medications.

Pharmacology	Gastrointestinal & Nutrition	Gastroesophageal reflux disease
Subject	System	Topic

Copyright © UWorld. All rights reserved.

1
2
3
4
5
6
7
8
9
10
11
12
13
14
15
16
17
18
19
20
21
22
23
24
25
26
27
28
29
30
31

A 34-year-old man is found to have dyslipidemia. His other medical problems include a myocardial infarction 1 week ago. His father died of myocardial infarction at the age of 48 years. Several other family members have had myocardial infarctions and hypertension. The patient smoked cigarettes and drank alcohol occasionally but quit after his myocardial infarction. He is started on simvastatin and cholestyramine. Which of the following best describes the independent effects of simvastatin and cholestyramine, respectively, on hepatic cholesterol synthesis?

A. Increase and increase

B. Increase and decrease

C. Decrease and increase

D. Decrease and decrease

E. Increase and no change

Submit

A 34-year-old man is found to have dyslipidemia. His other medical problems include a myocardial infarction 1 week ago. His father died of myocardial infarction at the age of 48 years. Several other family members have had myocardial infarctions and hypertension. The patient smoked cigarettes and drank alcohol occasionally but quit after his myocardial infarction. He is started on simvastatin and cholestyramine. Which of the following best describes the independent effects of simvastatin and cholestyramine, respectively, on hepatic cholesterol synthesis?

- A. Increase and increase (2%)
- B. Increase and decrease (2%)
- ✓ C. Decrease and increase (72%)
- D. Decrease and decrease (19%)
- E. Increase and no change (3%)

Omitted
Correct answer
C

72%
Answered correctly

01 sec
Time Spent

07/05/2020
Last Updated

Explanation

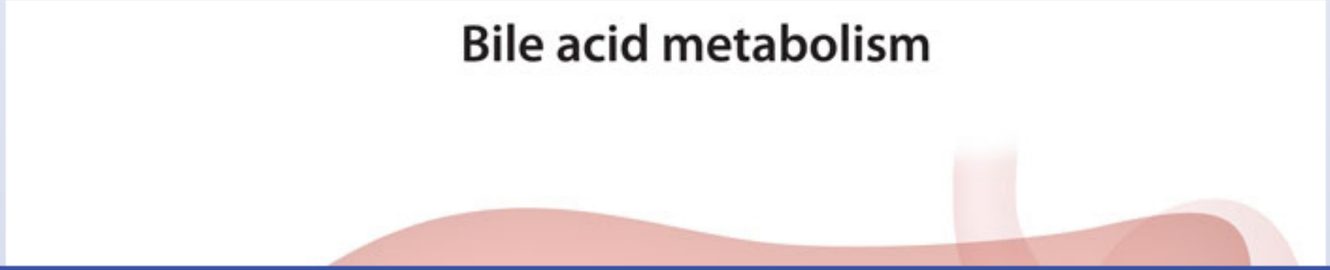

1
2
3
4
5
6
7
8
9
10
11
12
13
14
15
16
17
18
19
20
21
22
23
24
25
26
27
28
29
30
31

Bile acid metabolism

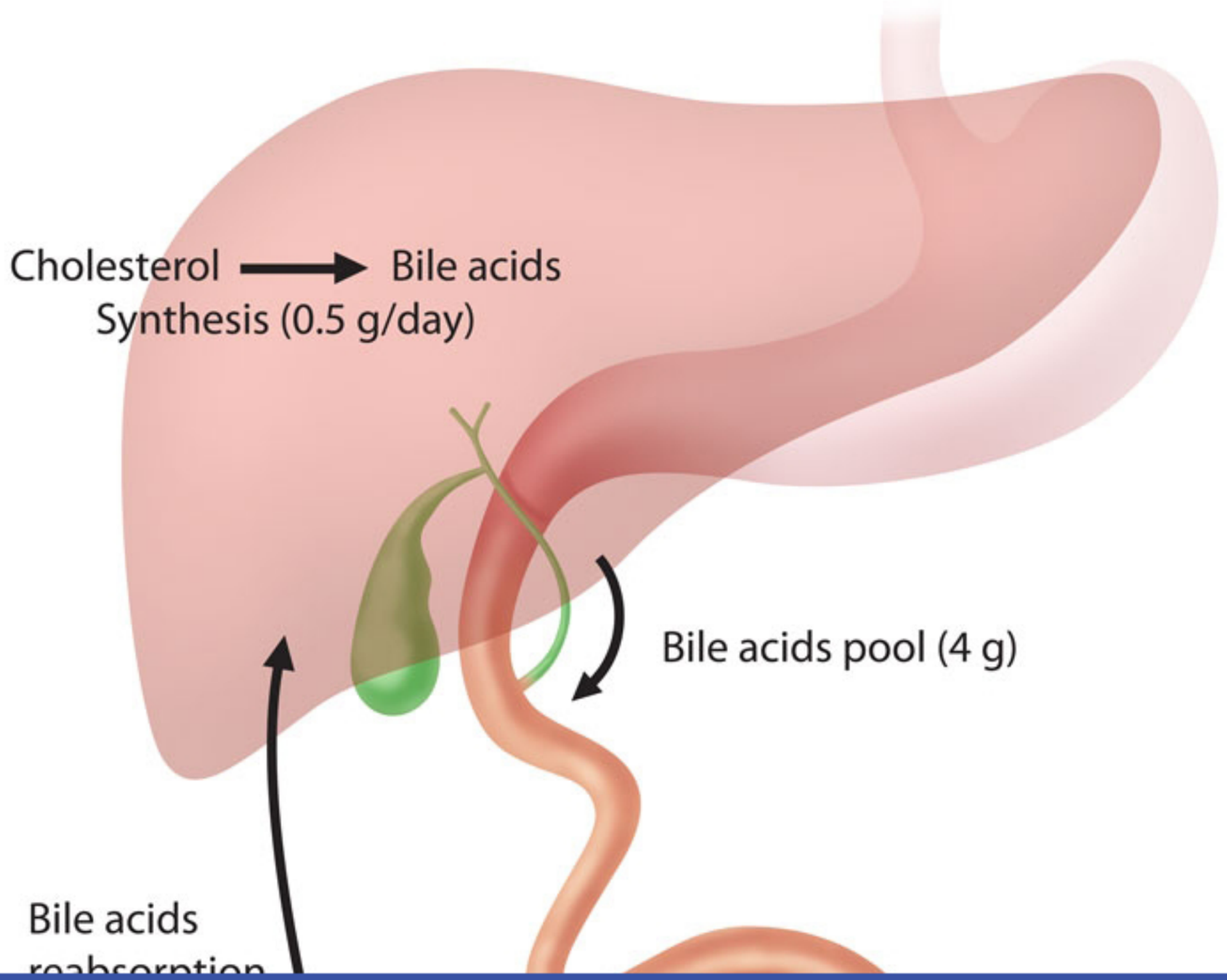

1
2
3
4
5
6
7
8
9
10
11
12
13
14
15
16
17
18
19
20
21
22
23
24
25
26
27
28
29
30
31

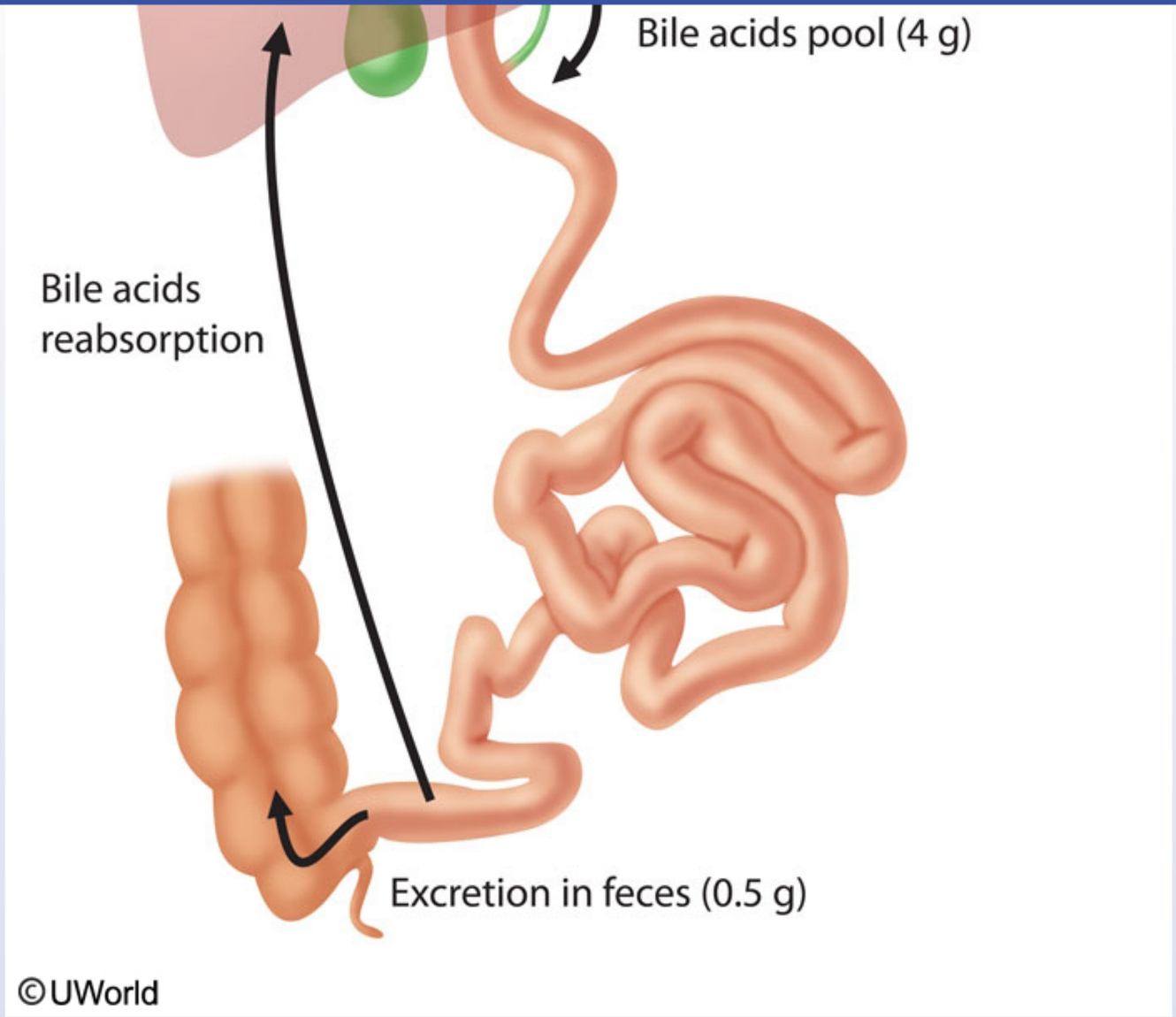

Bile acids are synthesized in the liver from cholesterol catabolism. Bile enters the duodenum through gallbladder contraction. Bile acids are

©UWorld

Bile acids are synthesized in the liver from cholesterol catabolism. Bile enters the duodenum through gallbladder contraction. Bile acids are primarily absorbed in the terminal ileum, with the small amount that remains unabsorbed being excreted in the stool (this amount is matched by bile acid synthesis).

Statins are the first-line therapy for most patients with hypercholesterolemia. These drugs competitively **inhibit HMG CoA reductase**, the enzyme responsible for the conversion of HMG CoA to mevalonate (ie, the rate-limiting step in hepatic cholesterol synthesis). This inhibition **decreases hepatic cholesterol synthesis**. The resulting upregulation of LDL receptors causes increased uptake of LDL from the circulation. Statins are very effective in reducing LDL cholesterol. Statins' effects on triglyceride and HDL levels are comparatively modest.

Bile acid–binding resins (ie, bile acid sequestrants) work by binding bile acids in the gastrointestinal tract, thereby interfering with the enterohepatic circulation of bile acids and causing increased bile acid excretion. This results in hepatic **synthesis of new bile acids**, a process that consumes liver cholesterol stores. Hepatic uptake of LDL from the circulation is increased for continued bile acid synthesis. Bile acid production and secretion are increased by 10-fold due to this interruption of the enterohepatic circulation of bile acids. Hepatic cholesterol reduction is an activating factor for HMG CoA reductase and subsequently results in **increased hepatic cholesterol synthesis**. This effect can be blocked with the addition of a statin drug to the treatment regimen, leading to a greater reduction in LDL levels than with use of either drug alone (synergistic action).

Educational objective:
Simvastatin decreases hepatic cholesterol production, while cholestyramine increases hepatic cholesterol and bile acid synthesis. Combination therapy results in a synergistic reduction in plasma LDL level.

References

- Overview of pharmacologic therapy for the treatment of dyslipidemia.

Pharmacology	Gastrointestinal & Nutrition	Dyslipidemia
Subject	System	Topic

Copyright © UWorld. All rights reserved.

1
2
3
4
5
6
7
8
9
10
11
12
13
14
15
16
17
18
19
20
21
22
23
24
25
26
27
28
29
30
31

A 57-year-old man with a history of alcoholic cirrhosis is brought to the emergency department due to altered mental status. Over the weekend, he ate a lot of smoked meats at a local barbecue competition. Since then, he has been sleeping most of the day and is confused and disoriented when awake. On examination, he has abdominal distension with shifting dullness. The patient answers correctly when asked for his name but does not know that he is in the hospital and says the year is "1997." When asked to extend his hands as if stopping traffic, the patient makes rhythmic flapping movements. He is started on rifaximin. Which of the following is the most likely mechanism of action of this drug when used to treat this patient's current condition?

A. Binding of dietary phosphate

B. Decreased intraluminal ammonia production

C. Exchange of intraluminal sodium ions for potassium ions

D. Formation of a nonabsorbable complex with bile acids

E. Increased conversion of ammonia to ammonium ion

Submit

A 57-year-old man with a history of alcoholic cirrhosis is brought to the emergency department due to altered mental status. Over the weekend, he ate a lot of smoked meats at a local barbecue competition. Since then, he has been sleeping most of the day and is confused and disoriented when awake. On examination, he has abdominal distension with shifting dullness. The patient answers correctly when asked for his name but does not know that he is in the hospital and says the year is "1997." When asked to extend his hands as if stopping traffic, the patient makes rhythmic flapping movements. He is started on rifaximin. Which of the following is the most likely mechanism of action of this drug when used to treat this patient's current condition?

A. Binding of dietary phosphate (1%)

✓ B. Decreased intraluminal ammonia production (47%)

C. Exchange of intraluminal sodium ions for potassium ions (1%)

D. Formation of a nonabsorbable complex with bile acids (3%)

E. Increased conversion of ammonia to ammonium ion (45%)

Omitted
Correct answer
B

47%
Answered correctly

01 sec
Time Spent

03/15/2020
Last Updated

Explanation

This patient likely has **hepatic encephalopathy** (HE), a neurologic complication of **cirrhosis** due in part to the liver's inability to convert **ammonia** (a neurotoxin) to urea. Excess ammonia is shunted past the liver and crosses the blood-brain barrier, leading to **altered mental status** (thought due to impaired neurotransmitter release, astrocyte dysfunction, neuroinflammation, and/or edema). Asterixis, the rhythmic flapping of dorsiflexed hands, is another common manifestation of HE.

This patient likely has **hepatic encephalopathy** (HE), a neurologic complication of **cirrhosis** due in part to the liver's inability to convert **ammonia** (a neurotoxin) to urea. Excess ammonia is shunted past the liver and crosses the blood-brain barrier, leading to **altered mental status** (thought due to impaired neurotransmitter release, astrocyte dysfunction, neuroinflammation, and/or edema). Asterixis, the rhythmic flapping of dorsiflexed hands, is another common manifestation of HE.

A primary source of ammonia is degradation of nitrogen products by intestinal bacteria. Therefore, **gastrointestinal (GI) bleeding** can precipitate HE as hemoglobin breakdown leads to increased nitrogen products in the gut. **Excess dietary protein intake** (eg, large steak meal) is another common trigger. Others include infection, sedatives, and metabolic derangements (eg, hypokalemia).

Rifaximin is a nonabsorbable antibiotic that alters GI flora to decrease intestinal production and absorption of ammonia. In patients with HE, rifaximin is generally used in addition to **lactulose**, which is catabolized by intestinal bacterial flora to short chain fatty acids, lowering the colonic pH and increasing conversion of ammonia to ammonium **(Choice E)**. Rifaximin is also sometimes used for traveler's diarrhea, as it inhibits bacterial RNA synthesis through binding with DNA-dependent RNA polymerase.

(Choices A and C) Phosphate binders (eg, calcium acetate) lower serum phosphate in patients with end-stage renal disease. Sodium polystyrene resin (eg, sodium polystyrene sulfonate) exchanges intraluminal sodium for potassium ions and can lower serum potassium in patients with hyperkalemia. However, neither effectively treats HE.

(Choice D) Bile acid sequestrants (cholestyramine, colestipol) bind intestinal bile acids to lower serum cholesterol, but they are not used for treating HE.

Educational objective:
Treatments for hepatic encephalopathy include lactulose (increases conversion of ammonia to ammonium) and rifaximin (decreases intraluminal ammonia production).

References

- Treatment options for hepatic encephalopathy.

Pharmacology	Gastrointestinal & Nutrition	Cirrhosis
Subject	System	Topic

1
2
3
4
5
6
7
8
9
10
11
12
13
14
15
16
17
18
19
20
21
22
23
24
25
26
27
28
29
30
31

A 45-year-old woman comes to the office for evaluation of dysphagia. The patient's symptoms first began 2 years ago with regurgitation and bloating after meals but have recently progressed to difficulty swallowing both solid foods and liquids. She has been using antacids without relief. The patient has no other medical history. She drinks 1 or 2 beers on weekends but does not smoke or use illicit drugs. Family history is unremarkable. Vital signs are within normal limits. BMI is 21 kg/m^2. The abdomen is nontender and soft with normal active bowel sounds. The patient undergoes upper endoscopy that shows a dilated esophagus and retained food. Esophageal manometry reveals increased lower esophageal sphincter (LES) tone and incomplete relaxation. Peristalsis is absent in the distal esophagus. Injection of which of the following into the patient's LES would most likely help relieve her symptoms?

A. Botulinum toxin
B. Corticosteroids
C. Neostigmine
D. Phenylephrine
E. Pilocarpine

Submit

A 45-year-old woman comes to the office for evaluation of dysphagia. The patient's symptoms first began 2 years ago with regurgitation and bloating after meals but have recently progressed to difficulty swallowing both solid foods and liquids. She has been using antacids without relief. The patient has no other medical history. She drinks 1 or 2 beers on weekends but does not smoke or use illicit drugs. Family history is unremarkable. Vital signs are within normal limits. BMI is 21 kg/m^2. The abdomen is nontender and soft with normal active bowel sounds. The patient undergoes upper endoscopy that shows a dilated esophagus and retained food. Esophageal manometry reveals increased lower esophageal sphincter (LES) tone and incomplete relaxation. Peristalsis is absent in the distal esophagus. Injection of which of the following into the patient's LES would most likely help relieve her symptoms?

- ✓ A. Botulinum toxin (78%)
- B. Corticosteroids (1%)
- C. Neostigmine (9%)
- D. Phenylephrine (2%)
- E. Pilocarpine (7%)

Omitted
Correct answer
A

78%
Answered correctly

02 secs
Time Spent

02/12/2020
Last Updated

Explanation

Achalasia is an esophageal motility disorder characterized by the absence of esophageal peristalsis in the distal esophagus and incomplete relaxation of a **hypertonic lower esophageal sphincter** (LES). Achalasia is caused by the immune-mediated **destruction of inhibitory ganglion cells** in the esophageal wall. Nitric oxide–producing neurons in the myenteric plexus that are responsible for esophageal smooth

Explanation

Achalasia is an esophageal motility disorder characterized by the absence of esophageal peristalsis in the distal esophagus and incomplete relaxation of a **hypertonic lower esophageal sphincter** (LES). Achalasia is caused by the immune-mediated **destruction of inhibitory ganglion cells** in the esophageal wall. Nitric oxide–producing neurons in the myenteric plexus that are responsible for esophageal smooth muscle relaxation are preferentially destroyed, whereas excitatory cholinergic neurons responsible for smooth muscle contraction are relatively spared. This imbalance results in increased lower esophageal tone and impaired sphincter relaxation.

Botulinum toxin, a neurotoxin formed by *Clostridium botulinum*, prevents the fusion of acetylcholine-containing synaptic vesicles with the plasma membrane. This effectively prevents acetylcholine release into the neuromuscular synapse, resulting in muscle weakness and paralysis. In a patient with achalasia, injection of **botulinum toxin** into the LES causes **cholinergic blockade**, leading to sphincter relaxation and symptomatic improvement.

(Choices B and D) In addition to the cholinergic neurons, there are multiple other hormones and neurotransmitters that modulate esophageal tone. Prostaglandins promote LES relaxation, whereas alpha-adrenergic agonists, such as phenylephrine, increase LES tone. Because corticosteroids inhibit prostaglandin synthesis, both corticosteroids and phenylephrine would worsen the patient's symptoms.

(Choices C and E) Neostigmine is a cholinesterase inhibitor and pilocarpine is a cholinergic agonist. Both of these medications increase cholinergic stimuli at the LES and would worsen the patient's symptoms.

Educational objective:
Achalasia is caused by loss of inhibitory ganglion cells in the distal esophageal wall and is characterized by the absence of esophageal peristalsis and incomplete relaxation of a hypertonic lower esophageal sphincter. Botulinum toxin prevents acetylcholine release into the neuromuscular synapse, resulting in inhibition of cholinergic neurons and lower esophageal sphincter relaxation.

Pharmacology	Gastrointestinal & Nutrition	Achalasia
Subject	System	Topic

Copyright © UWorld. All rights reserved.

1
2
3
4
5
6
7
8
9
10
11
12
13
14
15
16
17
18
19
20
21
22
23
24
25
26
27
28
29
30
31

Exhibit Display

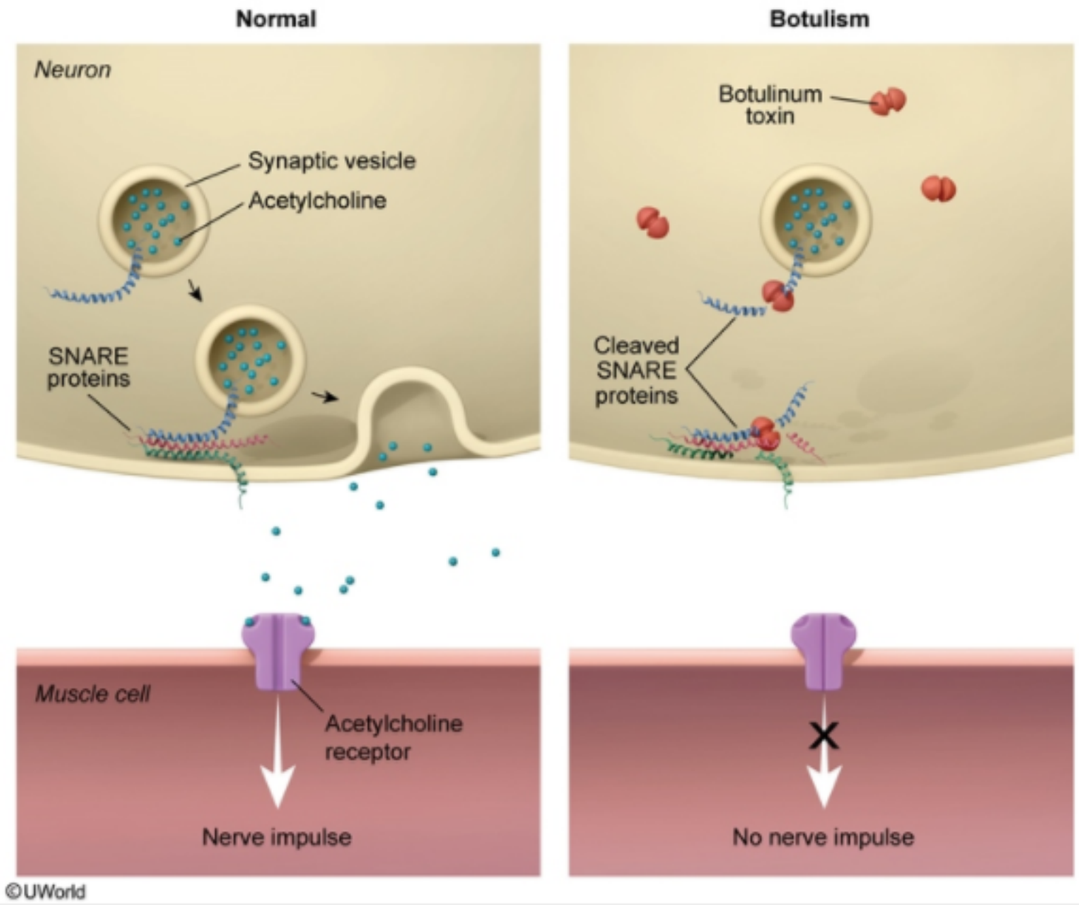

Zoom In Zoom Out Reset Add To Flash Card

1
2
3
4
5
6
7
8
9
10
11
12
13
14
15
16
17
18
19
20
21
22
23
24
25
26
27
28
29
30
31

A 32-year-old man comes to the office due to a substernal burning sensation that has been occurring intermittently over the last 6 months. The sensation worsens with spicy and fatty meals and is associated with food regurgitation and a sour taste in the back of the throat. He has no projectile vomiting, dysphagia, or unexpected weight loss. Medical history is significant for cystic fibrosis complicated by pancreatic insufficiency, for which the patient takes pancreatic enzyme replacement therapy with all meals. Vital signs are within normal limits. The abdomen is soft and nontender. He is prescribed omeprazole with subsequent improvement in his gastroesophageal reflux symptoms. In this patient, absorption of which of the following nutrients will likely improve due to initiation of this new medication?

A. Amino acids
B. Calcium
C. Dietary fat
D. Iron
E. Magnesium

Submit

A 32-year-old man comes to the office due to a substernal burning sensation that has been occurring intermittently over the last 6 months. The sensation worsens with spicy and fatty meals and is associated with food regurgitation and a sour taste in the back of the throat. He has no projectile vomiting, dysphagia, or unexpected weight loss. Medical history is significant for cystic fibrosis complicated by pancreatic insufficiency, for which the patient takes pancreatic enzyme replacement therapy with all meals. Vital signs are within normal limits. The abdomen is soft and nontender. He is prescribed omeprazole with subsequent improvement in his gastroesophageal reflux symptoms. In this patient, absorption of which of the following nutrients will likely improve due to initiation of this new medication?

- A. Amino acids (22%)
- B. Calcium (13%)
- ✓ C. Dietary fat (36%)
- D. Iron (18%)
- E. Magnesium (8%)

Omitted
Correct answer
C

36%
Answered correctly

03 secs
Time Spent

06/29/2020
Last Updated

Explanation

Proton pump inhibitors	
Mechanism of action	• Irreversible inhibition of parietal cell hydrogen-potassium-ATPase
	• Gastroesophageal reflux disease

Proton pump inhibitors	
Mechanism of action	• Irreversible inhibition of parietal cell hydrogen-potassium-ATPase
Common uses	• Gastroesophageal reflux disease • Peptic ulcer disease
Adverse effects	• Malabsorption of calcium, iron, magnesium & vitamin B_{12} ◦ Enhances fat absorption in patients given pancreatic enzyme replacement therapy • Increases risk of infection (eg, *Clostridioides* [formerly *Clostridium*] *difficile*, pneumonia) • Osteoporosis, chronic kidney disease, SIBO

SIBO = small intestinal bacterial overgrowth.

This patient with heartburn and regurgitation has the classic manifestations of gastroesophageal reflux disease, a common disorder that occurs when gastric acid refluxes into the esophagus. The mainstay of therapy is gastric acid suppression, usually with **proton pump inhibitors** (PPIs) (eg, pantoprazole, omeprazole).

PPIs irreversibly inhibit the hydrogen-potassium-ATPase pump found in parietal cells, thereby inhibiting hydrochloric acid secretion into the stomach lumen. Although this effectively raises the stomach pH and prevents gastric acid irritation of the esophagus, the acidic environment of the stomach is necessary to absorb certain nutrients. Therefore, common adverse effects of PPIs include malabsorption of calcium, iron, magnesium, and vitamin B_{12} **(Choices B, D, and E)**.

Patients with **pancreatic insufficiency** (eg, cystic fibrosis, chronic pancreatitis) cannot synthesize the pancreatic enzymes required for digestion of protein, fat, and carbohydrates. As such, the condition is managed with pancreatic enzyme replacements, which contain varying amounts of lipase, amylase, and protease. Unlike amylase and protease, which are activated by the low pH of the stomach, **lipase**, which plays a vital role in fat digestion, is **inactivated by the acidic environment** of the stomach. Therefore, by decreasing gastric hydrochloric acid production, **PPI use increases lipase activity** (ie, it prevents exogenous lipase from being denatured as it passes through the stomach), **enhancing fat absorption** in patients dependent on pancreatic enzyme replacement therapy.

This patient with heartburn and regurgitation has the classic manifestations of gastroesophageal reflux disease, a common disorder that occurs when gastric acid refluxes into the esophagus. The mainstay of therapy is gastric acid suppression, usually with **proton pump inhibitors** (PPIs) (eg, pantoprazole, omeprazole).

PPIs irreversibly inhibit the hydrogen-potassium-ATPase pump found in parietal cells, thereby inhibiting hydrochloric acid secretion into the stomach lumen. Although this effectively raises the stomach pH and prevents gastric acid irritation of the esophagus, the acidic environment of the stomach is necessary to absorb certain nutrients. Therefore, common adverse effects of PPIs include malabsorption of calcium, iron, magnesium, and vitamin B_{12} **(Choices B, D, and E)**.

Patients with **pancreatic insufficiency** (eg, cystic fibrosis, chronic pancreatitis) cannot synthesize the pancreatic enzymes required for digestion of protein, fat, and carbohydrates. As such, the condition is managed with pancreatic enzyme replacements, which contain varying amounts of lipase, amylase, and protease. Unlike amylase and protease, which are activated by the low pH of the stomach, **lipase**, which plays a vital role in fat digestion, is **inactivated by the acidic environment** of the stomach. Therefore, by decreasing gastric hydrochloric acid production, **PPI use increases lipase activity** (ie, it prevents exogenous lipase from being denatured as it passes through the stomach), **enhancing fat absorption** in patients dependent on pancreatic enzyme replacement therapy.

(Choice A) Protein digestion of amino acids requires the activity of a protease known as pepsin, which is more active at low pH. Although one might expect the elevated stomach pH to inhibit protein absorption, chronic PPI use has not been associated with protein malabsorption (likely due to functional overlap with pancreatic and enteric proteases).

Educational objective:
Proton pump inhibitors (PPI) prevent the hydrogen-potassium-ATPase pump found in parietal cells from releasing hydrochloric acid into the stomach lumen. Chronic PPI use protects exogenously administered lipase and enhances fat absorption in patients dependent on pancreatic enzyme replacement therapy.

References

- Optimising the therapy of exocrine pancreatic insufficiency by the association of a proton pump inhibitor to enteric coated pancreatic extracts.
- Proton pump inhibitors and risk of vitamin and mineral deficiency: evidence and clinical implications.

Pharmacology Gastrointestinal & Nutrition Proton pump inhibitors

PPIs irreversibly inhibit the hydrogen-potassium-ATPase pump found in parietal cells, thereby inhibiting hydrochloric acid secretion into the stomach lumen. Although this effectively raises the stomach pH and prevents gastric acid irritation of the esophagus, the acidic environment of the stomach is necessary to absorb certain nutrients. Therefore, common adverse effects of PPIs include malabsorption of calcium, iron, magnesium, and vitamin B_{12} **(Choices B, D, and E)**.

Patients with **pancreatic insufficiency** (eg, cystic fibrosis, chronic pancreatitis) cannot synthesize the pancreatic enzymes required for digestion of protein, fat, and carbohydrates. As such, the condition is managed with pancreatic enzyme replacements, which contain varying amounts of lipase, amylase, and protease. Unlike amylase and protease, which are activated by the low pH of the stomach, **lipase**, which plays a vital role in fat digestion, is **inactivated by the acidic environment** of the stomach. Therefore, by decreasing gastric hydrochloric acid production, **PPI use increases lipase activity** (ie, it prevents exogenous lipase from being denatured as it passes through the stomach), **enhancing fat absorption** in patients dependent on pancreatic enzyme replacement therapy.

(Choice A) Protein digestion of amino acids requires the activity of a protease known as pepsin, which is more active at low pH. Although one might expect the elevated stomach pH to inhibit protein absorption, chronic PPI use has not been associated with protein malabsorption (likely due to functional overlap with pancreatic and enteric proteases).

Educational objective:
Proton pump inhibitors (PPI) prevent the hydrogen-potassium-ATPase pump found in parietal cells from releasing hydrochloric acid into the stomach lumen. Chronic PPI use protects exogenously administered lipase and enhances fat absorption in patients dependent on pancreatic enzyme replacement therapy.

References

- Optimising the therapy of exocrine pancreatic insufficiency by the association of a proton pump inhibitor to enteric coated pancreatic extracts.
- Proton pump inhibitors and risk of vitamin and mineral deficiency: evidence and clinical implications.

Pharmacology	Gastrointestinal & Nutrition	Proton pump inhibitors
Subject	System	Topic

Copyright © UWorld. All rights reserved.

- Malabsorption of calcium, iron, magnesium & vitamin B_{12}

Exhibit Display

Parietal cell acid secretion

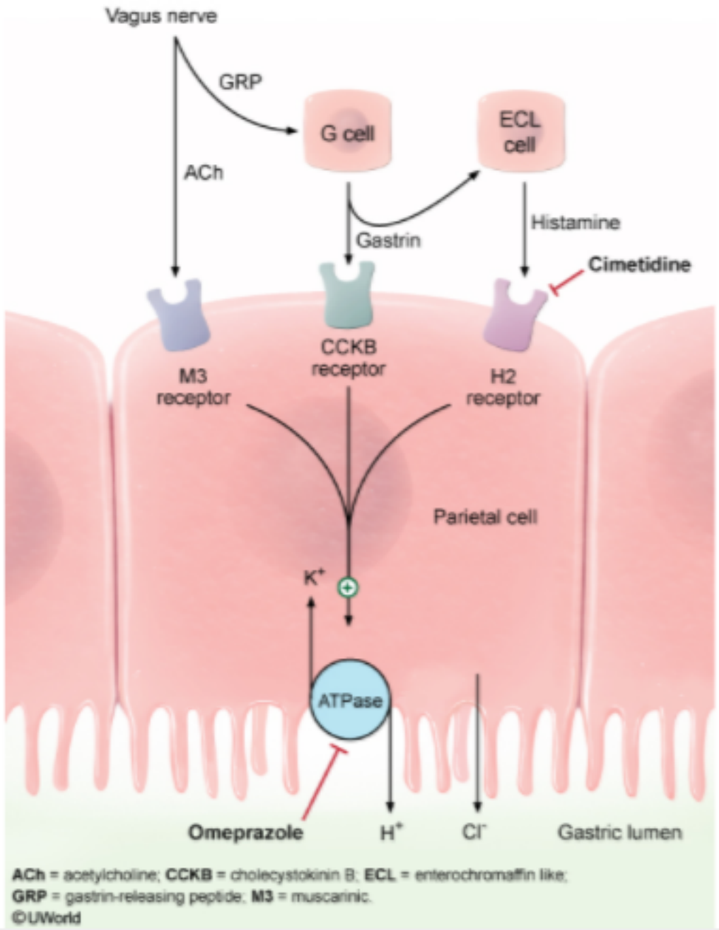

ACh = acetylcholine; **CCKB** = cholecystokinin B; **ECL** = enterochromaffin like; **GRP** = gastrin-releasing peptide; **M3** = muscarinic.
©UWorld

Zoom In Zoom Out Reset Add To Flash Card

stomach lumen. Chronic PPI use protects exogenously administered lipase and enhances fat absorption in patients dependent on pancreatic

A 62-year-old woman comes to the office due to a change in bowel habits. For 2 months, she has had bowel movements once every 5 or 6 days. The patient describes her stools as hard and lumpy and of small volume; defecation is uncomfortable. She has no trouble passing gas and has no other symptoms, including no nausea, vomiting, or weight changes. The patient was admitted to the hospital 3 months ago for acute diverticulitis, and her hospital course was complicated by new-onset atrial fibrillation. Colonoscopy a month after hospitalization revealed sigmoid diverticulosis but no masses or polyps. The patient takes fiber supplements, diltiazem, and apixaban. She does not use tobacco or alcohol. Vital signs are within normal limits. Cardiac auscultation reveals an irregular heart rhythm but no murmurs. Abdominal examination is significant for mild distension. Which of the following best explains this patient's symptoms?

- A. Alterations in colonic microbiome
- B. Gastrocolic reflex impairment
- C. Inappropriate contraction of pelvic floor muscles
- D. Medication adverse effects
- E. Posterior vaginal wall prolapse
- F. Sigmoid volvulus

Submit

A 62-year-old woman comes to the office due to a change in bowel habits. For 2 months, she has had bowel movements once every 5 or 6 days. The patient describes her stools as hard and lumpy and of small volume; defecation is uncomfortable. She has no trouble passing gas and has no other symptoms, including no nausea, vomiting, or weight changes. The patient was admitted to the hospital 3 months ago for acute diverticulitis, and her hospital course was complicated by new-onset atrial fibrillation. Colonoscopy a month after hospitalization revealed sigmoid diverticulosis but no masses or polyps. The patient takes fiber supplements, diltiazem, and apixaban. She does not use tobacco or alcohol. Vital signs are within normal limits. Cardiac auscultation reveals an irregular heart rhythm but no murmurs. Abdominal examination is significant for mild distension. Which of the following best explains this patient's symptoms?

- A. Alterations in colonic microbiome (6%)
- B. Gastrocolic reflex impairment (11%)
- C. Inappropriate contraction of pelvic floor muscles (2%)
- ✓ D. Medication adverse effects (66%)
- E. Posterior vaginal wall prolapse (3%)
- F. Sigmoid volvulus (9%)

Omitted
Correct answer
D

66%
Answered correctly

03 secs
Time Spent

05/02/2020
Last Updated

Explanation

Common medications associated with constipation

Explanation

Common medications associated with constipation	
Opioids	• Centrally acting (eg, oxycodone, morphine) • Peripherally acting (eg, loperamide)
Anticholinergic agents	• Antihistamines (eg, diphenhydramine) • Tricyclic antidepressants (eg, amitriptyline) • Antispasmodics (eg, dicyclomine) • 1st-generation antipsychotics (eg, haloperidol)
Cation-containing agents	• Iron tablets • Aluminum (eg, antacids)
Non–dihydropyridine calcium channel blockers	• Diltiazem, verapamil
5HT$_3$ antagonists	• Ondansetron, granisetron

5-HT$_3$ = 5-hydroxytryptamine type 3.

Constipation is an exceedingly common gastrointestinal condition with a wide variety of underlying etiologies (eg, autonomic neuropathy, hypothyroidism, electrolyte abnormalities). In this patient who developed constipation after new-onset atrial fibrillation, the most likely etiology is a **drug effect** related to diltiazem.

Diltiazem and verapamil are **non–dihydropyridine calcium channel blockers** that decrease conduction velocity in the sinoatrial and atrioventricular nodes and are often used in the management of atrial fibrillation. Constipation, a common adverse effect, occurs due to inhibition of the colonic migrating motor complex, resulting in **slowed contractions of colonic smooth muscle**. This is not typically seen with dihydropyridine calcium channel blockers (eg, amlodipine, nifedipine).

Constipation is an exceedingly common gastrointestinal condition with a wide variety of underlying etiologies (eg, autonomic neuropathy, hypothyroidism, electrolyte abnormalities). In this patient who developed constipation after new-onset atrial fibrillation, the most likely etiology is a **drug effect** related to diltiazem.

Diltiazem and verapamil are **non–dihydropyridine calcium channel blockers** that decrease conduction velocity in the sinoatrial and atrioventricular nodes and are often used in the management of atrial fibrillation. Constipation, a common adverse effect, occurs due to inhibition of the colonic migrating motor complex, resulting in **slowed contractions of colonic smooth muscle**. This is not typically seen with dihydropyridine calcium channel blockers (eg, amlodipine, nifedipine).

Other common medications that cause constipation include opiates, serotonin 5-HT_3 antagonists (eg, ondansetron), iron tablets, aluminum-containing agents (eg, antacids), and medications with anticholinergic properties (eg, diphenhydramine, tricyclic antidepressants, first-generation antipsychotics).

(Choice A) Alterations in the colonic microbiome are common after antibiotic therapy but typically cause diarrhea (eg, *Clostridioides* [formerly *Clostridium*] *difficile* colitis), not constipation.

(Choice B) The gastrocolic reflex is a neurogenic reflex triggered by gastric distension from food, leading to colonic contractions; impairment of the reflex can cause constipation. However, this typically occurs in patients with diabetic neuropathy and gastroparesis.

(Choice C) Inappropriate contraction of pelvic floor muscles occurs with dyssenergic defecation, preventing the expulsion of stool from the rectum. Dyssenergic defecation is more common in the elderly and often associated with neurologic disorders (eg, Parkinson disease) or trauma. The development of symptoms after this patient started diltiazem is more consistent with medication-induced constipation.

(Choice E) A rectocele, which occurs when the rectum prolapses into the posterior vaginal wall, usually develops in elderly, multiparous women. Although constipation is common, patients usually describe pelvic pressure and the need to manually push on the vagina or rectum to defecate.

(Choice F) Sigmoid volvulus typically presents with progressive abdominal pain, nausea, and constipation and eventually results in bowel obstruction (eg, failure to pass gas, obstipation, possible perforation). Symptoms occur over the course of days, not months.

Educational objective:
Constipation is a common adverse effect of non–dihydropyridine calcium channel blockers (eg, diltiazem, verapamil). Other medications that cause constipation include opiates, 5-HT_3 antagonists, iron tablets, aluminum-containing antacids, and medications with anticholinergic properties

antipsychotics).

(Choice A) Alterations in the colonic microbiome are common after antibiotic therapy but typically cause diarrhea (eg, *Clostridioides* [formerly *Clostridium*] *difficile* colitis), not constipation.

(Choice B) The gastrocolic reflex is a neurogenic reflex triggered by gastric distension from food, leading to colonic contractions; impairment of the reflex can cause constipation. However, this typically occurs in patients with diabetic neuropathy and gastroparesis.

(Choice C) Inappropriate contraction of pelvic floor muscles occurs with dyssenergic defecation, preventing the expulsion of stool from the rectum. Dyssenergic defecation is more common in the elderly and often associated with neurologic disorders (eg, Parkinson disease) or trauma. The development of symptoms after this patient started diltiazem is more consistent with medication-induced constipation.

(Choice E) A rectocele, which occurs when the rectum prolapses into the posterior vaginal wall, usually develops in elderly, multiparous women. Although constipation is common, patients usually describe pelvic pressure and the need to manually push on the vagina or rectum to defecate.

(Choice F) Sigmoid volvulus typically presents with progressive abdominal pain, nausea, and constipation and eventually results in bowel obstruction (eg, failure to pass gas, obstipation, possible perforation). Symptoms occur over the course of days, not months.

Educational objective:
Constipation is a common adverse effect of non–dihydropyridine calcium channel blockers (eg, diltiazem, verapamil). Other medications that cause constipation include opiates, 5-HT_3 antagonists, iron tablets, aluminum-containing antacids, and medications with anticholinergic properties.

References

- Effects of 5-hydroxytryptamine (serotonin) type 3 antagonists on symptom relief and constipation in nonconstipated irritable bowel syndrome: a systematic review and meta-analysis of randomized controlled trials.
- Nifedipine and verapamil inhibit the sigmoid colon myoelectric response to eating in healthy volunteers.

Pharmacology	Gastrointestinal & Nutrition	Constipation
Subject	System	Topic

Copyright © UWorld. All rights reserved.

1
2
3
4
5
6
7
8
9
10
11
12
13
14
15
16
17
18
19
20
21
22
23
24
25
26
27
28
29
30
31

A 42-year-old woman comes to the office with persistent hyperlipidemia despite 6 months of maintaining a healthy diet and exercising regularly. Although her past medical history is significant for biliary colic secondary to gallstones, the patient has refused elective cholecystectomy. Her father died of a myocardial infarction at age 54, and her mother has diabetes mellitus. The patient's temperature is 36.1 C (97 F), blood pressure is 122/79 mm Hg, pulse is 78/min, and respirations are 14/min. Examination shows no abnormalities. Laboratory studies obtained 1 week ago show elevated serum triglycerides and LDL cholesterol levels. Drug therapy is discussed with the patient. Given this patient's preexisting gallbladder disease, which of the following drugs should be avoided?

A. Atorvastatin
B. Ezetimibe
C. Fish oil
D. Gemfibrozil
E. Niacin

Submit

A 42-year-old woman comes to the office with persistent hyperlipidemia despite 6 months of maintaining a healthy diet and exercising regularly. Although her past medical history is significant for biliary colic secondary to gallstones, the patient has refused elective cholecystectomy. Her father died of a myocardial infarction at age 54, and her mother has diabetes mellitus. The patient's temperature is 36.1 C (97 F), blood pressure is 122/79 mm Hg, pulse is 78/min, and respirations are 14/min. Examination shows no abnormalities. Laboratory studies obtained 1 week ago show elevated serum triglycerides and LDL cholesterol levels. Drug therapy is discussed with the patient. Given this patient's preexisting gallbladder disease, which of the following drugs should be avoided?

- A. Atorvastatin (7%)
- B. Ezetimibe (18%)
- C. Fish oil (4%)
- ✓ D. Gemfibrozil (64%)
- E. Niacin (6%)

Omitted
Correct answer
D

64%
Answered correctly

02 secs
Time Spent

01/15/2020
Last Updated

Explanation

1
2
3
4
5
6
7
8
9
10
11
12
13
14
15
16
17
18
19
20
21
22
23
24
25
26
27
28
29
30
31

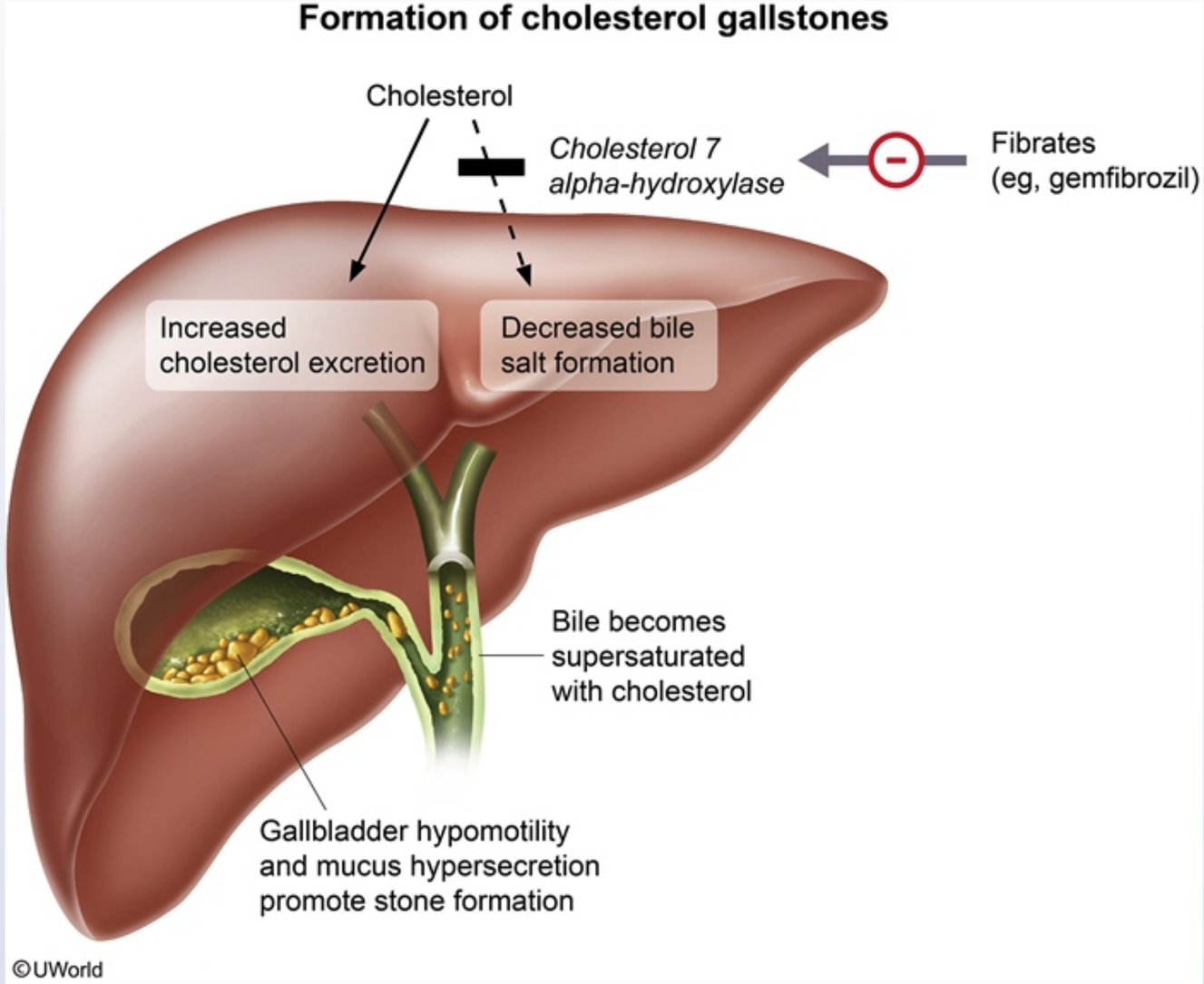

In patients with significant **hypertriglyceridemia**, fibrates are particularly effective due to their ability to upregulate lipoprotein lipase resulting in

In patients with significant **hypertriglyceridemia**, fibrates are particularly effective due to their ability to upregulate lipoprotein lipase resulting in increased oxidation of fatty acids (liver, muscles). Gemfibrozil and other **fibrates** inhibit the rate-limiting enzyme in bile acid synthesis, cholesterol 7-alpha-hydroxylase. The reduced bile acid production results in **decreased cholesterol solubility** and increased microcrystal precipitation, thereby **promoting gallstone formation**. As a result, fibrates should be used with caution in patients with preexisting gallbladder disease. Patients on fibrate therapy should also be monitored for myopathy, a risk significantly increased when fibrates are used concurrently with statins.

(Choice A) Long-term use of statins (eg, atorvastatin) is associated with decreased risk of gallstone disease as inhibition of HMG-CoA reductase reduces cholesterol biosynthesis and bile supersaturation. Side effects of statin therapy include hepatic dysfunction (elevated aminotransferases) and myopathy.

(Choice B) Ezetimibe blocks intestinal cholesterol absorption, decreasing liver cholesterol stores and reducing biliary cholesterol content. Adverse effects associated with ezetimibe include elevated transaminases (increased with concurrent use of statins) and diarrhea.

(Choice C) Fish oil supplements containing high concentrations of omega-3 fatty acids increase bile acid synthesis, decrease cholesterol saturation in bile, and increase gallbladder motility. The net effect is a decreased risk of gallstone formation.

(Choice E) Niacin increases HDL (via reduced catabolism) and lowers triglyceride levels (through inhibition of VLDL secretion). It is associated with lower rates of gallstone disease. Niacin commonly promotes flushing, a temporary prostaglandin-mediated effect often blunted by use of nonsteroidal anti-inflammatory drugs.

Educational objective:
Gemfibrozil (and other fibrates) can reduce cholesterol solubility and promote gallstone formation by reducing bile acid synthesis. Caution should be used when prescribing fibrate therapy to patients with underlying gallbladder disease.

References

- Triglycerides and gallstone formation.

Pharmacology	Gastrointestinal & Nutrition	Dyslipidemia
Subject	System	Topic

Copyright © UWorld. All rights reserved.

1
2
3
4
5
6
7
8
9
10
11
12
13
14
15
16
17
18
19
20
21
22
23
24
25
26
27
28
29
30
31

A 23-year-old woman comes to the physician due to acute nausea and vomiting. She recently returned from a vacation to Mexico and started to feel "queasy" on the last day of her trip. The patient then developed nausea with frequent vomiting and intermittent bouts of watery diarrhea. She has no visible blood in her stools. Her temperature is 36.8 C (98 F), blood pressure is 118/70 mm Hg, pulse is 86/min, and respirations are 12/min. Abdominal examination shows mild tenderness and increased bowel sounds. Improvement of this patient's vomiting would best be achieved by a medication targeting which of the following receptors?

A. 5-HT_3 receptor
B. μ-opioid receptor
C. Dopamine receptor
D. Histamine H_1 receptor
E. Histamine H_2 receptor
F. Muscarinic acetylcholine receptor
G. Somatostatin receptor

Submit

A 23-year-old woman comes to the physician due to acute nausea and vomiting. She recently returned from a vacation to Mexico and started to feel "queasy" on the last day of her trip. The patient then developed nausea with frequent vomiting and intermittent bouts of watery diarrhea. She has no visible blood in her stools. Her temperature is 36.8 C (98 F), blood pressure is 118/70 mm Hg, pulse is 86/min, and respirations are 12/min. Abdominal examination shows mild tenderness and increased bowel sounds. Improvement of this patient's vomiting would best be achieved by a medication targeting which of the following receptors?

- ✓ A. 5-HT_3 receptor (55%)
- B. μ-opioid receptor (9%)
- C. Dopamine receptor (11%)
- D. Histamine H_1 receptor (5%)
- E. Histamine H_2 receptor (3%)
- F. Muscarinic acetylcholine receptor (13%)
- G. Somatostatin receptor (2%)

Omitted
Correct answer
A

55%
Answered correctly

02 secs
Time Spent

03/09/2020
Last Updated

Explanation

Physiologic causes of nausea

1
2
3
4
5
6
7
8
9
10
11
12
13
14
15
16
17
18
19
20
21
22
23
24
25
26
27
28
29
30
31

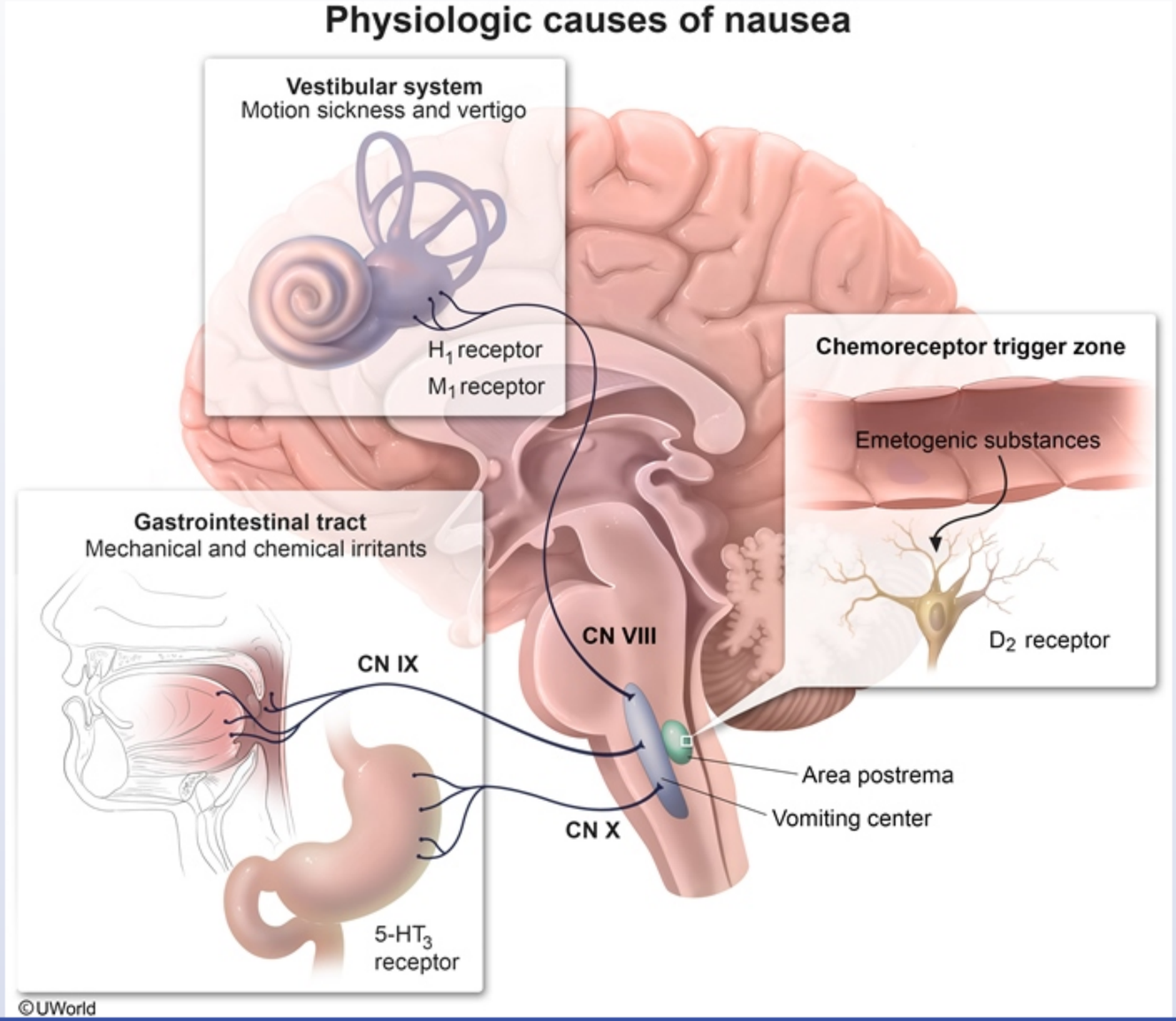

This patient's nausea, vomiting, and watery diarrhea are typical symptoms of classic **travelers' diarrhea (TD)**. TD can be caused by a variety of organisms, including bacteria (eg, *Escherichia coli*), viruses (eg, rotaviruses), or occasionally, parasites (eg, *Cryptosporidium parvum*). In most cases, the illness is self-limited and treatment is symptomatic.

The choice of antiemetic therapy depends on the source of the emetogenic stimulus. Conditions that cause **gastrointestinal irritation** (eg, infections, chemotherapy, distention) result in increased mucosal **serotonin** release and activation of 5-HT_3 receptors on vagal and spinal afferent nerves. These then relay their impulses to the medullary vomiting center, inducing emesis. **5-HT_3 receptor antagonists** (eg, ondansetron) are well-tolerated medications that are very effective at reducing nausea and vomiting caused by gastrointestinal upset.

(Choice B) Loperamide is a μ-opioid receptor agonist that functions as an antimotility agent. It is commonly used in TD to reduce diarrhea but can worsen nausea and vomiting due to colonic retention.

(Choice C) Dopamine receptor antagonists (eg, metoclopramide, prochlorperazine) are effective in treating central nausea (seen in acute migraines) and also reduce migraine headache pain. Dopamine antagonists have significant adverse effects including sedation and extrapyramidal symptoms; these are not the first-line treatment for nausea due to gastrointestinal upset.

(Choices D and F) First-generation H_1 receptor antagonists (eg, diphenhydramine, meclizine) and muscarinic acetylcholine receptor antagonists (eg, scopolamine) are frequently used to treat vestibular nausea (eg, motion sickness). Promethazine is a dopamine and H_1 receptor antagonist that can also treat vestibular nausea. All of these medications can cause significant sedation.

(Choice E) H_2 blockers (eg, ranitidine) reduce gastric acid secretion and can alleviate symptoms of gastroesophageal reflux but do not treat nausea and vomiting.

(Choice G) Somatostatin receptor agonists (eg, octreotide) inhibit bioactive amine release and are used to treat diarrhea in patients with carcinoid syndrome and vasoactive intestinal peptide-secreting tumors (ie, VIPoma). They are also used for treatment of acute esophageal variceal hemorrhage.

Educational objective:
5-HT_3 receptor antagonists are useful for the treatment of visceral nausea due to gastrointestinal insults, such as gastroenteritis, chemotherapy, and general anesthesia. Antihistamines and anticholinergics are recommended for vestibular nausea. Dopamine antagonists are useful for nausea associated with migraine.

(Choice B) Loperamide is a μ-opioid receptor agonist that functions as an antimotility agent. It is commonly used in TD to reduce diarrhea but can worsen nausea and vomiting due to colonic retention.

(Choice C) Dopamine receptor antagonists (eg, metoclopramide, prochlorperazine) are effective in treating central nausea (seen in acute migraines) and also reduce migraine headache pain. Dopamine antagonists have significant adverse effects including sedation and extrapyramidal symptoms; these are not the first-line treatment for nausea due to gastrointestinal upset.

(Choices D and F) First-generation H_1 receptor antagonists (eg, diphenhydramine, meclizine) and muscarinic acetylcholine receptor antagonists (eg, scopolamine) are frequently used to treat vestibular nausea (eg, motion sickness). Promethazine is a dopamine and H_1 receptor antagonist that can also treat vestibular nausea. All of these medications can cause significant sedation.

(Choice E) H_2 blockers (eg, ranitidine) reduce gastric acid secretion and can alleviate symptoms of gastroesophageal reflux but do not treat nausea and vomiting.

(Choice G) Somatostatin receptor agonists (eg, octreotide) inhibit bioactive amine release and are used to treat diarrhea in patients with carcinoid syndrome and vasoactive intestinal peptide-secreting tumors (ie, VIPoma). They are also used for treatment of acute esophageal variceal hemorrhage.

Educational objective:
5-HT_3 receptor antagonists are useful for the treatment of visceral nausea due to gastrointestinal insults, such as gastroenteritis, chemotherapy, and general anesthesia. Antihistamines and anticholinergics are recommended for vestibular nausea. Dopamine antagonists are useful for nausea associated with migraine.

References

- Use of antiemetic agents in acute gastroenteritis: a systematic review and meta-analysis.

Pharmacology	Gastrointestinal & Nutrition	Antiemetics
Subject	System	Topic

Copyright © UWorld. All rights reserved.

1
2
3
4
5
6
7
8
9
10
11
12
13
14
15
16
17
18
19
20
21
22
23
24
25
26
27
28
29
30
31

A 42-year-old man comes to the office due to increased abdominal girth associated with a 9-kg (19.8-lb) weight gain over the past month. He drinks a liter of vodka daily and denies smoking or using intravenous drugs. Blood pressure is 110/70 mm Hg. The abdomen is moderately distended, and a fluid wave is elicited. Multiple spider angiomas are present. Laboratory studies reveal thrombocytopenia, hypoalbuminemia, a normal sodium level, and an elevated PT. An upper endoscopy is performed, which shows no esophageal or gastric varices. Pharmacotherapy aimed at inhibiting which of the following should be considered for this patient?

A. Aldosterone

B. Alpha-adrenergic receptors

C. Angiotensin

D. Antidiuretic hormone

E. Prostaglandins

Submit

A 42-year-old man comes to the office due to increased abdominal girth associated with a 9-kg (19.8-lb) weight gain over the past month. He drinks a liter of vodka daily and denies smoking or using intravenous drugs. Blood pressure is 110/70 mm Hg. The abdomen is moderately distended, and a fluid wave is elicited. Multiple spider angiomas are present. Laboratory studies reveal thrombocytopenia, hypoalbuminemia, a normal sodium level, and an elevated PT. An upper endoscopy is performed, which shows no esophageal or gastric varices. Pharmacotherapy aimed at inhibiting which of the following should be considered for this patient?

- ✓ A. Aldosterone (48%)
- B. Alpha-adrenergic receptors (6%)
- C. Angiotensin (14%)
- D. Antidiuretic hormone (22%)
- E. Prostaglandins (9%)

Omitted
Correct answer
A

48%
Answered correctly

02 secs
Time Spent

03/13/2020
Last Updated

Explanation

This patient with abdominal distension and a fluid wave has **ascites**. His heavy alcohol use and evidence of chronic liver disease (eg, spider angiomas, thrombocytopenia, hypoalbuminemia, elevated PT) suggest the ascites developed due to **alcoholic cirrhosis**.

In cirrhosis, portal hypertension leads to splanchnic vasodilation, which decreases the effective arterial volume and lowers the systemic blood pressure. Renal perfusion is reduced, leading to activation of the **renin-angiotensin-aldosterone system** (RAAS), which promotes vasoconstriction (due to angiotensin) and fluid and sodium retention by the kidneys (due to aldosterone). Although this improves systemic blood

This patient with abdominal distension and a fluid wave has **ascites**. His heavy alcohol use and evidence of chronic liver disease (eg, spider angiomas, thrombocytopenia, hypoalbuminemia, elevated PT) suggest the ascites developed due to **alcoholic cirrhosis**.

In cirrhosis, portal hypertension leads to splanchnic vasodilation, which decreases the effective arterial volume and lowers the systemic blood pressure. Renal perfusion is reduced, leading to activation of the **renin-angiotensin-aldosterone system** (RAAS), which promotes vasoconstriction (due to angiotensin) and fluid and sodium retention by the kidneys (due to aldosterone). Although this improves systemic blood pressure and renal perfusion, due to the altered hemodynamics in patients with cirrhosis (eg, elevated hydrostatic pressure due to portal hypertension, low oncotic pressure due to hypoalbuminemia) it ultimately results in third spacing of fluid with edema and ascites.

Spironolactone, an **aldosterone antagonist**, is used to interrupt this cycle. It induces natriuresis without blocking the critical vasoconstrictive effects of angiotensin. Spironolactone is typically used with furosemide (a loop diuretic) to increase the efficacy of natriuresis and prevent electrolyte disturbances.

(Choices B and C) Patients with cirrhosis have low mean arterial pressure due to splanchnic vasodilation and are dependent on the RAAS to help normalize blood pressure and renal perfusion. ACE inhibitors (eg, lisinopril) and angiotensin receptor blockers blunt this critical response and promote organ hypoperfusion. Likewise, blockade of alpha-adrenergic receptors would cause widespread vasodilation with decreased systemic blood pressure, worsening renal perfusion and causing additional fluid accumulation.

(Choice D) Antidiuretic hormone (ADH) levels are increased in cirrhosis, which contributes to the development of hypervolemic hyponatremia. Although ADH inhibitors (eg, tolvapatan) have been used to treat severe hyponatremia in cirrhosis, they are not indicated in patients with normal sodium levels.

(Choice E) Nonsteroidal anti-inflammatory drugs inhibit prostaglandin production, which can cause renal vasoconstriction and may precipitate gastrointestinal bleeding. These medications should be avoided in patients with cirrhosis due to impaired renal perfusion at baseline and high risk of variceal bleeding.

Educational objective:
Ascites in cirrhosis develops from hemodynamic changes related to portal hypertension. Splanchnic vasodilation decreases the systemic vascular resistance, which causes activation of the renin-angiotensin-aldosterone system and promotes vasoconstriction and sodium and water retention. Spironolactone, an aldosterone antagonist, is used to induce natriuresis and resolve ascites without blocking the critical vasoconstrictive effects of angiotensin.

effects of angiotensin. Spironolactone is typically used with furosemide (a loop diuretic) to increase the efficacy of natriuresis and prevent electrolyte disturbances.

(Choices B and C) Patients with cirrhosis have low mean arterial pressure due to splanchnic vasodilation and are dependent on the RAAS to help normalize blood pressure and renal perfusion. ACE inhibitors (eg, lisinopril) and angiotensin receptor blockers blunt this critical response and promote organ hypoperfusion. Likewise, blockade of alpha-adrenergic receptors would cause widespread vasodilation with decreased systemic blood pressure, worsening renal perfusion and causing additional fluid accumulation.

(Choice D) Antidiuretic hormone (ADH) levels are increased in cirrhosis, which contributes to the development of hypervolemic hyponatremia. Although ADH inhibitors (eg, tolvapatan) have been used to treat severe hyponatremia in cirrhosis, they are not indicated in patients with normal sodium levels.

(Choice E) Nonsteroidal anti-inflammatory drugs inhibit prostaglandin production, which can cause renal vasoconstriction and may precipitate gastrointestinal bleeding. These medications should be avoided in patients with cirrhosis due to impaired renal perfusion at baseline and high risk of variceal bleeding.

Educational objective:
Ascites in cirrhosis develops from hemodynamic changes related to portal hypertension. Splanchnic vasodilation decreases the systemic vascular resistance, which causes activation of the renin-angiotensin-aldosterone system and promotes vasoconstriction and sodium and water retention. Spironolactone, an aldosterone antagonist, is used to induce natriuresis and resolve ascites without blocking the critical vasoconstrictive effects of angiotensin.

References

- Introduction to the revised American Association for the Study of Liver Diseases practice guideline management of adult patients with ascites due to cirrhosis 2012.

Pharmacology	Gastrointestinal & Nutrition	Ascites
Subject	System	Topic

Copyright © UWorld. All rights reserved.

A new medication, drug A, is being developed for the treatment of peptic ulcer disease. During initial testing, gastric acid secretion in experimental animals is stimulated by vagal stimulation, histamine infusion, or gastrin infusion. Before the stimulus is administered, the animals are divided into 2 groups, one group receives pretreatment with drug A, and the second one serves as the control and is given an injection of an equivalent volume of normal saline. The effects of the drug on hydrochloric acid (HCl) output by the stomach mucosa are recorded and shown in the graphs below.

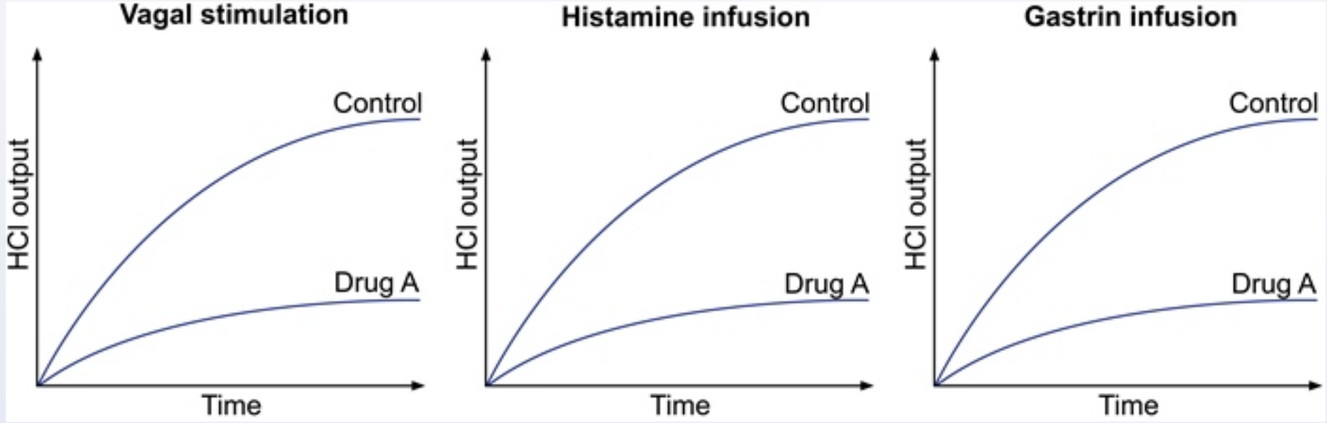

Drug A is most similar to which of the following medications?

A. Atropine
B. Bethanechol
C. Cimetidine
D. Lansoprazole
E. Sucralfate

1
2
3
4
5
6
7
8
9
10
11
12
13
14
15
16
17
18
19
20
21
22
23
24
25
26
27
28
29
30
31

A new medication, drug A, is being developed for the treatment of peptic ulcer disease. During initial testing, gastric acid secretion in experimental animals is stimulated by vagal stimulation, histamine infusion, or gastrin infusion. Before the stimulus is administered, the animals are divided into 2 groups, one group receives pretreatment with drug A, and the second one serves as the control and is given an injection of an equivalent volume of normal saline. The effects of the drug on hydrochloric acid (HCl) output by the stomach mucosa are recorded and shown in the graphs below.

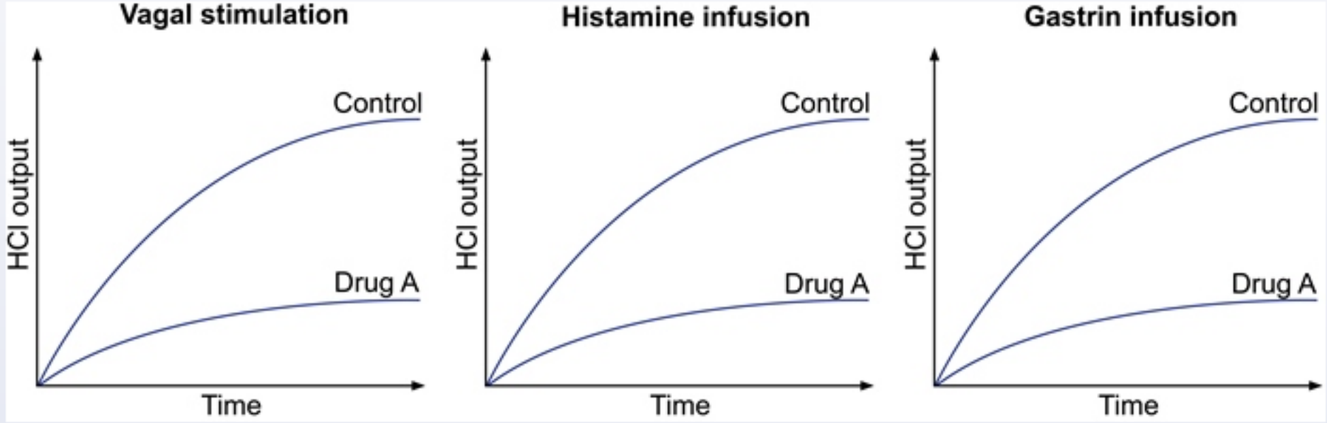

Drug A is most similar to which of the following medications?

A. Atropine (10%)
B. Bethanechol (2%)
C. Cimetidine (10%)
✓ D. Lansoprazole (73%)
E. Sucralfate (2%)

1
2
3
4
5
6
7
8
9
10
11
12
13
14
15
16
17
18
19
20
21
22
23
24
25
26
27
28
29
30
31

Parietal cell acid secretion

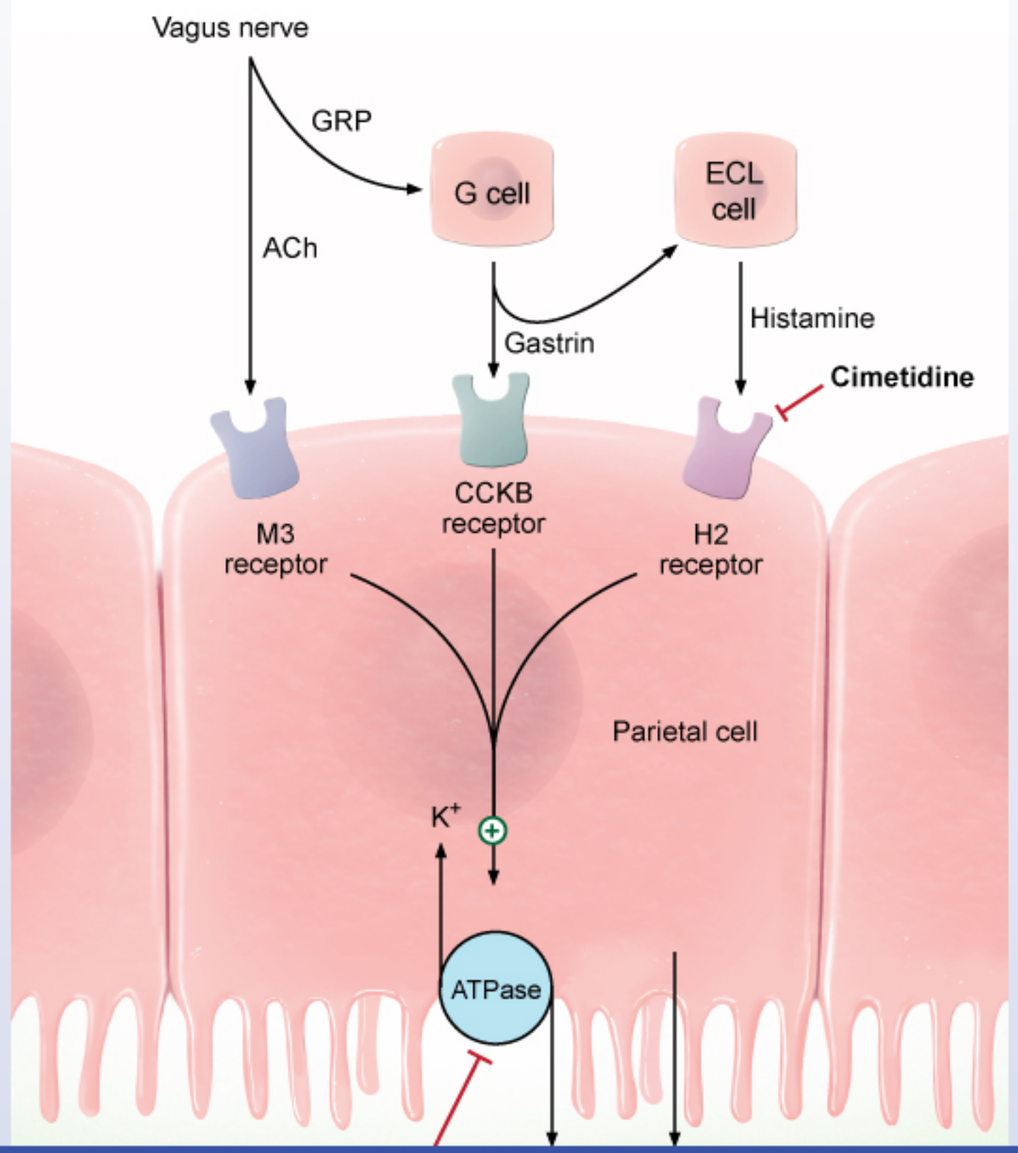

Gastric **parietal cells** secrete **hydrochloric acid** (HCl) in response to 3 major stimulants: histamine, vagal output, and gastrin.

1. **Histamine** is released from enterochromaffin-like (ECL) cells and binds to H2 receptors on the basolateral parietal cell membrane.
2. Vagal stimulation causes **acetylcholine** release, which directly stimulates HCl secretion by binding to parietal cell muscarinic (M3) receptors. In addition, vagal stimulation indirectly promotes HCl secretion via gastrin-releasing peptide (GRP), which stimulates gastrin release from G cells.
3. G cells also release **gastrin** in response to protein-rich meals. Gastrin primarily stimulates HCl secretion by binding to the CCK_B receptor on ECL cells (promotes histamine release). It also directly binds to the CCK_B receptor on parietal cells, but this mechanism is less significant for acid secretion.

The **final common pathway** for HCl secretion is the **H^+/K^+-ATPase proton pump**, located on the apical membrane of the parietal cell. Based on the graphs shown above, drug A inhibits gastric acid secretion in response to all 3 major stimulants. Therefore, drug A is most similar to a proton pump inhibitor (eg, **lansoprazole**, omeprazole) as it is likely inhibiting the H^+/K^+-ATPase proton pump.

(Choice A) Atropine is a nonselective antimuscarinic agent often used to produce mydriasis/cycloplegia or reverse bradycardia. Atropine may reduce gastric acid secretion in response to vagal stimulation by blocking parietal cell M3 receptors; however, it would not significantly decrease acid secretion during histamine or gastrin infusion.

(Choice B) Bethanechol is a cholinomimetic muscarinic agonist used to treat ileus and urinary retention. Bethanechol would promote gastric acid secretion by stimulating parietal cell M3 receptors.

(Choice C) Cimetidine treats gastroesophageal reflux and peptic ulcer disease by blocking parietal cell H2 receptors. Although H2 receptor blockade would reduce gastric acid secretion in response to histamine or gastrin infusion, it would not significantly reduce acid secretion in response to vagal stimulation.

(Choice E) Sucralfate may promote peptic ulcer healing by binding to the base of mucosal ulcers and providing physical protection against gastric acid; however, it does not inhibit gastric acid secretion.

Educational objective:
Proton pump inhibitors (eg, omeprazole, lansoprazole) block the final common pathway of gastric acid secretion from parietal cells, which is

the graphs shown above, drug A inhibits gastric acid secretion in response to all 3 major stimulants. Therefore, drug A is most similar to a proton pump inhibitor (eg, **lansoprazole**, omeprazole) as it is likely inhibiting the H^+/K^+-ATPase proton pump.

(Choice A) Atropine is a nonselective antimuscarinic agent often used to produce mydriasis/cycloplegia or reverse bradycardia. Atropine may reduce gastric acid secretion in response to vagal stimulation by blocking parietal cell M3 receptors; however, it would not significantly decrease acid secretion during histamine or gastrin infusion.

(Choice B) Bethanechol is a cholinomimetic muscarinic agonist used to treat ileus and urinary retention. Bethanechol would promote gastric acid secretion by stimulating parietal cell M3 receptors.

(Choice C) Cimetidine treats gastroesophageal reflux and peptic ulcer disease by blocking parietal cell H2 receptors. Although H2 receptor blockade would reduce gastric acid secretion in response to histamine or gastrin infusion, it would not significantly reduce acid secretion in response to vagal stimulation.

(Choice E) Sucralfate may promote peptic ulcer healing by binding to the base of mucosal ulcers and providing physical protection against gastric acid; however, it does not inhibit gastric acid secretion.

Educational objective:
Proton pump inhibitors (eg, omeprazole, lansoprazole) block the final common pathway of gastric acid secretion from parietal cells, which is stimulated by acetylcholine, histamine, and gastrin.

References

- Control of gastric acid secretion: the gastrin-ECL cell-parietal cell axis.
- Cell biology of gastric acid secretion.
- Revisiting the parietal cell.

Pharmacology	Gastrointestinal & Nutrition	Peptic ulcer disease
Subject	System	Topic

Copyright © UWorld. All rights reserved.

the graphs shown above, drug A inhibits gastric acid secretion in response to all 3 major stimulants. Therefore, drug A is most similar to a proton pump inhibitor (eg, **lansoprazole**, omeprazole) as it is likely inhibiting the H^+/K^+-ATPase proton pump.

(Choice A) Atropine is a nonselective antimuscarinic agent often used to produce mydriasis/cycloplegia or reverse bradycardia. Atropine may reduce gastric acid secretion in response to vagal stimulation by blocking parietal cell M3 receptors; however, it would not significantly decrease acid secretion during histamine or gastrin infusion.

(Choice B) Bethanechol is a cholinomimetic muscarinic agonist used to treat ileus and urinary retention. Bethanechol would promote gastric acid secretion by stimulating parietal cell M3 receptors.

(Choice C) Cimetidine treats gastroesophageal reflux and peptic ulcer disease by blocking parietal cell H2 receptors. Although H2 receptor blockade would reduce gastric acid secretion in response to histamine or gastrin infusion, it would not significantly reduce acid secretion in response to vagal stimulation.

(Choice E) Sucralfate may promote peptic ulcer healing by binding to the base of mucosal ulcers and providing physical protection against gastric acid; however, it does not inhibit gastric acid secretion.

Educational objective:
Proton pump inhibitors (eg, omeprazole, lansoprazole) block the final common pathway of gastric acid secretion from parietal cells, which is stimulated by acetylcholine, histamine, and gastrin.

References

- Control of gastric acid secretion: the gastrin-ECL cell-parietal cell axis.
- Cell biology of gastric acid secretion.
- Revisiting the parietal cell.

Pharmacology	Gastrointestinal & Nutrition	Peptic ulcer disease
Subject	System	Topic

Copyright © UWorld. All rights reserved.

1
2
3
4
5
6
7
8
9
10
11
12
13
14
15
16
17
18
19
20
21
22
23
24
25
26
27
28
29
30
31

A 72-year-old man comes to the office due to watery diarrhea and abdominal cramps. The symptoms began several days after he started chemotherapy for metastatic colon cancer. He denies hematochezia, melena, or bulky, foul-smelling stools. Vital signs are within normal limits, and physical examination is unremarkable. Laboratory testing reveals no electrolyte abnormalities and no leukocytosis. Stool testing is negative for infection and fecal occult blood. The patient is advised to take a medication after each loose stool. The medication works by inhibiting the release of acetylcholine in the intestinal wall but does not cross the blood-brain barrier. Which of the following is the most likely medication prescribed for this patient?

A. Aprepitant
B. Bismuth subsalicylate
C. Fentanyl
D. Loperamide
E. Neostigmine
F. Octreotide

Submit

A 72-year-old man comes to the office due to watery diarrhea and abdominal cramps. The symptoms began several days after he started chemotherapy for metastatic colon cancer. He denies hematochezia, melena, or bulky, foul-smelling stools. Vital signs are within normal limits, and physical examination is unremarkable. Laboratory testing reveals no electrolyte abnormalities and no leukocytosis. Stool testing is negative for infection and fecal occult blood. The patient is advised to take a medication after each loose stool. The medication works by inhibiting the release of acetylcholine in the intestinal wall but does not cross the blood-brain barrier. Which of the following is the most likely medication prescribed for this patient?

- A. Aprepitant (8%)
- B. Bismuth subsalicylate (5%)
- C. Fentanyl (1%)
- ✓ D. Loperamide (51%)
- E. Neostigmine (18%)
- F. Octreotide (14%)

Omitted
Correct answer
D

51%
Answered correctly

03 secs
Time Spent

02/20/2020
Last Updated

Explanation

Antidiarrheal agents	
Opioid agonists	

Antidiarrheal agents	
Opioid agonists (eg, loperamide, diphenoxylate with atropine, tincture of opium)	• Binds to mu opiate receptors in the colonic myenteric plexus, slowing peristalsis
Bulk forming agents (eg, psyllium, pectin)	• Absorbs water and intraluminal contents to form stool
Bismuth subsalicylate	• Stimulates intestinal fluid absorption and inhibits prostaglandin synthesis (antispasmotic effect)
Octreotide	• Somatostatin analog that reduces secretion of pancreatic and GI hormones
Bile acid sequestrants (eg, cholestyramine)	• Binds bile acid in intestines (used for bile-acid diarrhea)

GI = gastrointestinal.

This patient with uncomplicated, chemotherapy-induced diarrhea was prescribed **loperamide**. Loperamide is an **opioid agonist** that exerts its antidiarrheal effects by binding to **mu opiate receptors** in the colonic myenteric plexus. This **inhibits acetylcholine release** from myenteric plexus neurons, decreasing activity of the intestinal smooth muscles and **slowing peristalsis**. Transit time within the intestine is prolonged, allowing for increased water absorption. In addition, the anticholinergic effects also result in decreased secretion from the intestinal epithelia, further reducing stool volume and increasing fecal consistency.

Unlike other opiates (eg, hydrocodone, fentanyl), loperamide undergoes **high first-pass metabolism** and **does not cross the blood-brain barrier**, allowing it to be used without opiate-related adverse events (eg, respiratory depression, sedation) or threat of abuse. The only side effect is constipation, which can be avoided with careful dose titration. Diphenoxylate, another opiate used for diarrhea, is less extensively metabolized and crosses the blood-brain barrier. To discourage abuse, diphenoxylate is typically combined with a small amount of atropine, an anticholinergic medication that results in dry mouth, flushing, pupil dilation, and urinary retention when used in large amounts.

This patient with uncomplicated, chemotherapy-induced diarrhea was prescribed **loperamide**. Loperamide is an **opioid agonist** that exerts its antidiarrheal effects by binding to **mu opiate receptors** in the colonic myenteric plexus. This **inhibits acetylcholine release** from myenteric plexus neurons, decreasing activity of the intestinal smooth muscles and **slowing peristalsis**. Transit time within the intestine is prolonged, allowing for increased water absorption. In addition, the anticholinergic effects also result in decreased secretion from the intestinal epithelia, further reducing stool volume and increasing fecal consistency.

Unlike other opiates (eg, hydrocodone, fentanyl), loperamide undergoes **high first-pass metabolism** and **does not cross the blood-brain barrier**, allowing it to be used without opiate-related adverse events (eg, respiratory depression, sedation) or threat of abuse. The only side effect is constipation, which can be avoided with careful dose titration. Diphenoxylate, another opiate used for diarrhea, is less extensively metabolized and crosses the blood-brain barrier. To discourage abuse, diphenoxylate is typically combined with a small amount of atropine, an anticholinergic medication that results in dry mouth, flushing, pupil dilation, and urinary retention when used in large amounts.

(Choice A) Aprepitant is a neurokinin-1 receptor antagonist used for chemotherapy-related nausea and vomiting, not diarrhea.

(Choice B) Bismuth subsalicylate is frequently used for diarrhea and dyspepsia. Although its mechanism of action is not clearly understood, it stimulates the intestinal absorption of fluid (reducing diarrhea) and inhibits prostaglandin synthesis (reducing hypermotility). It does not inhibit acetylcholine release.

(Choice C) Fentanyl is an opiate commonly used as an analgesic and sedative. Although it causes constipation, it crosses the blood-brain barrier and therefore is not used for diarrhea due to the risk of systemic opiate-related adverse events (eg, respiratory depression, abuse).

(Choice E) Neostigmine is an acetylcholinesterase inhibitor that increases acetylcholine within the synapse. Its cholinergic effects would worsen this patient's diarrhea.

(Choice F) Octreotide is a somatostatin analogue that is sometimes used for refractory chemotherapy-induced diarrhea; however, it exerts its antidiarrheal effect by reducing secretion of pancreatic and gastrointestinal hormones (eg, secretin, gastrin, vasoactive intestinal peptide).

Educational objective:
Loperamide is an opioid agonist that exerts its antidiarrheal effects by binding to mu opiate receptors in the colonic myenteric plexus, which inhibits acetylcholine release, decreases intestinal smooth muscle activity, and slows peristalsis. It undergoes high first-pass metabolism and does not cross the blood-brain barrier, thus avoiding systemic opiate-related adverse events (eg, sedation, respiratory depression).

is constipation, which can be avoided with careful dose titration. Diphenoxylate, another opiate used for diarrhea, is less extensively metabolized and crosses the blood-brain barrier. To discourage abuse, diphenoxylate is typically combined with a small amount of atropine, an anticholinergic medication that results in dry mouth, flushing, pupil dilation, and urinary retention when used in large amounts.

(Choice A) Aprepitant is a neurokinin-1 receptor antagonist used for chemotherapy-related nausea and vomiting, not diarrhea.

(Choice B) Bismuth subsalicylate is frequently used for diarrhea and dyspepsia. Although its mechanism of action is not clearly understood, it stimulates the intestinal absorption of fluid (reducing diarrhea) and inhibits prostaglandin synthesis (reducing hypermotility). It does not inhibit acetylcholine release.

(Choice C) Fentanyl is an opiate commonly used as an analgesic and sedative. Although it causes constipation, it crosses the blood-brain barrier and therefore is not used for diarrhea due to the risk of systemic opiate-related adverse events (eg, respiratory depression, abuse).

(Choice E) Neostigmine is an acetylcholinesterase inhibitor that increases acetylcholine within the synapse. Its cholinergic effects would worsen this patient's diarrhea.

(Choice F) Octreotide is a somatostatin analogue that is sometimes used for refractory chemotherapy-induced diarrhea; however, it exerts its antidiarrheal effect by reducing secretion of pancreatic and gastrointestinal hormones (eg, secretin, gastrin, vasoactive intestinal peptide).

Educational objective:
Loperamide is an opioid agonist that exerts its antidiarrheal effects by binding to mu opiate receptors in the colonic myenteric plexus, which inhibits acetylcholine release, decreases intestinal smooth muscle activity, and slows peristalsis. It undergoes high first-pass metabolism and does not cross the blood-brain barrier, thus avoiding systemic opiate-related adverse events (eg, sedation, respiratory depression).

References

- Guidance on the management of diarrhoea during cancer chemotherapy.

Pharmacology	Gastrointestinal & Nutrition	Antidiarrheal agents
Subject	System	Topic

Copyright © UWorld. All rights reserved.

1
2
3
4
5
6
7
8
9
10
11
12
13
14
15
16
17
18
19
20
21
22
23
24
25
26
27
28
29
30
31

A 14-year-old Caucasian boy is brought to the physician by his mother due to chronic diarrhea and failure to gain weight appropriately. He has a history of recurrent respiratory infections, and prior sputum cultures have been positive for *Pseudomonas aeruginosa*. His younger brother died from a severe respiratory infection at age 9. Which of the following agents is most likely to improve this patient's condition in the long term?

- A. Antimotility agents
- B. Gluten-free diet
- C. Metronidazole
- D. Octreotide
- E. Pancreatic lipase
- F. Sulfasalazine

Submit

A 14-year-old Caucasian boy is brought to the physician by his mother due to chronic diarrhea and failure to gain weight appropriately. He has a history of recurrent respiratory infections, and prior sputum cultures have been positive for *Pseudomonas aeruginosa*. His younger brother died from a severe respiratory infection at age 9. Which of the following agents is most likely to improve this patient's condition in the long term?

- A. Antimotility agents (2%)
- B. Gluten-free diet (6%)
- C. Metronidazole (5%)
- D. Octreotide (5%)
- ✓ E. Pancreatic lipase (71%)
- F. Sulfasalazine (8%)

Omitted
Correct answer
E

71%
Answered correctly

04 secs
Time Spent

01/24/2020
Last Updated

Explanation

Features of cystic fibrosis	
Pathogenesis	• Autosomal recessive mutation (ΔF508) impairs CFTR function • Decreased water content causes thick, viscous mucus: ∘ Chronic airway obstruction

Explanation

Features of cystic fibrosis	

Pathogenesis	• Autosomal recessive mutation (ΔF508) impairs CFTR function
	• Decreased water content causes thick, viscous mucus:
	  ◦ Chronic airway obstruction
	  ◦ Gastrointestinal malabsorption

Clinical manifestations	• Chronic, productive cough • Recurrent sinopulmonary infections (especially *Staphylococcus aureus* & *Pseudomonas aeruginosa*) • Pancreatic insufficiency • Male infertility (bilateral absence of vas deferens)
Diagnosis	• Elevated sweat chloride levels • Nasal potential difference measurements • Genetic testing for *CFTR* mutations
CFTR = cystic fibrosis transmembrane conductance regulator.	

This young Caucasian patient has a history of recurrent respiratory infections caused by *Pseudomonas aeruginosa*, chronic diarrhea, and failure to thrive. These findings, along with a family history of early sibling death from pulmonary infection, suggest a diagnosis of cystic fibrosis. Steatorrhea and failure to thrive occur as a result of malabsorption due to obstructive fibrosis and progressive insufficiency of the exocrine pancreas. Pancreatic lipase supplementation is likely to improve this patient's condition by enhancing macronutrient and vitamin absorption.

(Choice A) Agents that decrease gastrointestinal motility (eg, opiates such as loperamide) can help decrease the volume of diarrhea by slowing intestinal transit time and allowing greater net fluid resorption. However, antimotility agents would not improve the deficiencies in nutrient

This young Caucasian patient has a history of recurrent respiratory infections caused by *Pseudomonas aeruginosa*, chronic diarrhea, and failure to thrive. These findings, along with a family history of early sibling death from pulmonary infection, suggest a diagnosis of cystic fibrosis. Steatorrhea and failure to thrive occur as a result of malabsorption due to obstructive fibrosis and progressive insufficiency of the exocrine pancreas. Pancreatic lipase supplementation is likely to improve this patient's condition by enhancing macronutrient and vitamin absorption.

(Choice A) Agents that decrease gastrointestinal motility (eg, opiates such as loperamide) can help decrease the volume of diarrhea by slowing intestinal transit time and allowing greater net fluid resorption. However, antimotility agents would not improve the deficiencies in nutrient absorption.

(Choice B) A gluten-free diet is the mainstay of treatment for celiac sprue but would be unlikely to help this patient's malabsorption.

(Choice C) Metronidazole is effective only for diarrhea due to infectious causes (eg, giardiasis). This patient's diarrhea is more likely due to malabsorption secondary to cystic fibrosis.

(Choice D) Octreotide is a somatostatin analogue that decreases gut motility, blood flow, and endocrine and exocrine pancreatic function. Octreotide decreases secretion of pancreatic enzymes into the intestine and could therefore aggravate this patient's malabsorptive diarrhea and associated nutritional deficiencies.

(Choice F) 5-aminosalicylates (eg, sulfasalazine, mesalamine) are used to treat inflammatory bowel diseases such as Crohn's disease and ulcerative colitis. They work by inhibiting cytokine, prostaglandin, and leukotriene synthesis during inflammation. This patient's diarrhea and weight loss are not caused by inflammation.

Educational objective:
In a young Caucasian patient, the combination of recurrent respiratory infections with *Pseudomonas aeruginosa*, diarrhea, and failure to thrive suggests a diagnosis of cystic fibrosis. Cystic fibrosis causes steatorrhea and failure to thrive due to malabsorption secondary to pancreatic insufficiency, which can be corrected by pancreatic enzyme supplementation.

Pharmacology	Gastrointestinal & Nutrition	Cystic fibrosis
Subject	System	Topic

Copyright © UWorld. All rights reserved.

1
2
3
4
5
6
7
8
9
10
11
12
13
14
15
16
17
18
19
20
21
22
23
24
25
26
27
28
29
30
31

A 40-year-old woman comes to the office with a 4-week history of diarrhea accompanied by occasional abdominal bloating. She has noticed that her stools contain mucus but has not seen any blood. The patient also has intermittent mild heartburn. She has no fevers, chills, or weight loss. The patient has also noticed an unpleasant taste with dairy products and now avoids them. Past medical history is significant for chronic allergic rhinitis. Current medications include only a multivitamin supplement. Vital signs and physical examination are normal. After a basic evaluation, the patient is started on a trial of diphenoxylate therapy. Which of the following is the primary target of this drug?

A. Absorption

B. Digestion

C. Inflammation

D. Motility

E. Secretion

Submit

A 40-year-old woman comes to the office with a 4-week history of diarrhea accompanied by occasional abdominal bloating. She has noticed that her stools contain mucus but has not seen any blood. The patient also has intermittent mild heartburn. She has no fevers, chills, or weight loss. The patient has also noticed an unpleasant taste with dairy products and now avoids them. Past medical history is significant for chronic allergic rhinitis. Current medications include only a multivitamin supplement. Vital signs and physical examination are normal. After a basic evaluation, the patient is started on a trial of diphenoxylate therapy. Which of the following is the primary target of this drug?

- A. Absorption (16%)
- B. Digestion (13%)
- C. Inflammation (10%)
- ✓ D. Motility (42%)
- E. Secretion (15%)

Omitted
Correct answer
D

42%
Answered correctly

02 secs
Time Spent

01/27/2020
Last Updated

Explanation

This patient has uncomplicated **diarrhea** with benign findings on initial examination and evaluation. Common causes include irritable bowel syndrome and functional diarrhea. In such cases, empiric symptomatic therapy is often considered prior to more complex testing.

Diphenoxylate is an opioid anti-diarrheal agent structurally related to meperidine. It binds to **mu opiate receptors** in the gastrointestinal tract and **slows motility**. Low doses relieve diarrhea without other significant opiate effects. However, higher doses can produce morphine-like euphoria and physical dependence. To discourage abuse, diphenoxylate is combined with atropine, which produces adverse symptoms (dry mouth, blurry

This patient has uncomplicated **diarrhea** with benign findings on initial examination and evaluation. Common causes include irritable bowel syndrome and functional diarrhea. In such cases, empiric symptomatic therapy is often considered prior to more complex testing.

Diphenoxylate is an opioid anti-diarrheal agent structurally related to meperidine. It binds to **mu opiate receptors** in the gastrointestinal tract and **slows motility**. Low doses relieve diarrhea without other significant opiate effects. However, higher doses can produce morphine-like euphoria and physical dependence. To discourage abuse, diphenoxylate is combined with atropine, which produces adverse symptoms (dry mouth, blurry vision, nausea) if taken in high doses. Loperamide is another low-potency opioid agonist used in the symptomatic treatment of diarrhea. Common side effects of these drugs include rebound constipation and mild sedation. They should not be used in diarrhea due to toxin-producing or invasive organisms (eg, *Shigella, Salmonella*) or *Clostridium difficile* infections.

(Choices A and B) Substances that are poorly digested or absorbed can retain fluid in the intestinal lumen and cause diarrhea. Lactase enzyme supplements are used in patients with lactase deficiency who have diarrhea due to undigested dietary lactose. Patients with exocrine pancreatic deficiency often have diarrhea due to undigested fats; pancreatic enzyme supplements are useful in these individuals.

(Choice C) Ulcerative colitis and Crohn disease are inflammatory bowel diseases that commonly present with diarrhea. Inflammation of the gut causes mucous, proteinaceous, and bloody discharge that leads to diarrhea. Treatment involves anti-inflammatory drugs, corticosteroids, and other immunosuppressive agents. This patient lacks inflammatory features.

(Choice E) Secretory diarrhea can be due to many different substances (eg, vasoactive intestinal peptide, bacterial toxins) that increase secretions. Agents that target secretory diarrhea include bismuth subsalicylate, octreotide, and possibly some probiotic preparations.

Educational objective:
Diphenoxylate is an opioid antidiarrheal drug that binds mu opiate receptors in the gut to slow motility. Overuse can lead to euphoria and physical dependence. To discourage abuse, diphenoxylate is combined with atropine, which induces adverse effects if taken in high doses.

Pharmacology	Gastrointestinal & Nutrition	Irritable bowel syndrome
Subject	System	Topic

Copyright © UWorld. All rights reserved.

1
2
3
4
5
6
7
8
9
10
11
12
13
14
15
16
17
18
19
20
21
22
23
24
25
26
27
28
29
30
31

A 62-year-old man comes to the office due to watery diarrhea. He has also been having episodes of dyspnea and wheezing. His wife has noticed that he sometimes becomes very flushed and red. The patient has no abdominal pain, vomiting, cough, or fever. He has a history of hypertension and takes amlodipine. He does not use tobacco, alcohol, or illicit drugs. His blood pressure is 140/70 mm Hg and pulse is 82/min. Cardiopulmonary examination is unremarkable. The abdomen is soft and nontender. Chest x-ray is normal, and the abdominal CT scan reveals mass lesions in the right liver lobe and ileum. Surgery is scheduled to resect the tumors. Which of the following medications can be used to relieve this patient's symptoms prior to surgery?

A. Cabergoline
B. Leuprolide
C. Octreotide
D. Phenoxybenzamine
E. Rituximab

Submit

A 62-year-old man comes to the office due to watery diarrhea. He has also been having episodes of dyspnea and wheezing. His wife has noticed that he sometimes becomes very flushed and red. The patient has no abdominal pain, vomiting, cough, or fever. He has a history of hypertension and takes amlodipine. He does not use tobacco, alcohol, or illicit drugs. His blood pressure is 140/70 mm Hg and pulse is 82/min. Cardiopulmonary examination is unremarkable. The abdomen is soft and nontender. Chest x-ray is normal, and the abdominal CT scan reveals mass lesions in the right liver lobe and ileum. Surgery is scheduled to resect the tumors. Which of the following medications can be used to relieve this patient's symptoms prior to surgery?

A. Cabergoline (4%)
B. Leuprolide (5%)
✓ C. Octreotide (75%)
D. Phenoxybenzamine (12%)
E. Rituximab (2%)

Omitted
Correct answer
C

75%
Answered correctly

02 secs
Time Spent

06/01/2020
Last Updated

Explanation

Features of carcinoid syndrome	
	• Skin: **Flushing**, telangiectasias, cyanosis

Features of carcinoid syndrome	
Clinical manifestations	• Skin: **Flushing**, telangiectasias, cyanosis • Gastrointestinal: **Watery diarrhea**, cramping • Pulmonary: **Bronchospasm**, dyspnea, wheezing • Cardiac: Valvular fibrous plaques (right > left)
Diagnosis	• Elevated 24-hour urinary excretion of **5-HIAA** • CT/MRI of abdomen & pelvis to localize tumor
Treatment	• Octreotide for symptomatic patients • Surgery for liver metastases

5-HIAA = 5-hydroxyindoleacetic acid.

©UWorld

The combination of wheezing, diarrhea, and facial flushing in association with an ileal tumor with hepatic metastasis is suggestive of **carcinoid syndrome**. Carcinoid tumors (most common ileal tumors) secrete a number of biologically active substances including serotonin and can cause symptoms when they metastasize. Common manifestations of carcinoid syndrome include flushing, asthma-like symptoms (wheezing, dyspnea), diarrhea, and syncope (due to low blood pressure). Long-standing carcinoid syndrome can cause right-sided valvular heart disease.

The most definitive treatment for carcinoid syndrome is surgical excision. Medical therapy with octreotide can be used to control symptoms. **Octreotide** is a synthetic analog of somatostatin with a longer half-life. It acts on somatostatin receptors and inhibits secretion of many hormones and hormone-like substances. Octreotide is also used to inhibit secretory diarrhea in VIPomas (pancreatic endocrine tumors).

(Choice A) Cabergoline is a dopamine agonist used in growth hormone-secreting pituitary tumors or prolactinoma.

(Choice B) Leuprolide is a synthetic analog of gonadotropin-releasing hormone (GnRH). Continuous administration suppresses release of LH and FSH. Leuprolide is used in management of prostatic cancer, precocious puberty, and endometriosis.

5-HIAA = 5-hydroxyindoleacetic acid.

©UWorld

The combination of wheezing, diarrhea, and facial flushing in association with an ileal tumor with hepatic metastasis is suggestive of **carcinoid syndrome**. Carcinoid tumors (most common ileal tumors) secrete a number of biologically active substances including serotonin and can cause symptoms when they metastasize. Common manifestations of carcinoid syndrome include flushing, asthma-like symptoms (wheezing, dyspnea), diarrhea, and syncope (due to low blood pressure). Long-standing carcinoid syndrome can cause right-sided valvular heart disease.

The most definitive treatment for carcinoid syndrome is surgical excision. Medical therapy with octreotide can be used to control symptoms. **Octreotide** is a synthetic analog of somatostatin with a longer half-life. It acts on somatostatin receptors and inhibits secretion of many hormones and hormone-like substances. Octreotide is also used to inhibit secretory diarrhea in VIPomas (pancreatic endocrine tumors).

(Choice A) Cabergoline is a dopamine agonist used in growth hormone-secreting pituitary tumors or prolactinoma.

(Choice B) Leuprolide is a synthetic analog of gonadotropin-releasing hormone (GnRH). Continuous administration suppresses release of LH and FSH. Leuprolide is used in management of prostatic cancer, precocious puberty, and endometriosis.

(Choice D) Phenoxybenzamine is an alpha blocker that is used in treatment of pheochromocytoma.

(Choice E) Rituximab is a CD20 monoclonal antibody used to treat multiple myeloma, leukemia, and multiple autoimmune disorders.

Educational objective:
Carcinoid syndrome may accompany extraintestinal metastases of gastrointestinal carcinoid tumors. Octreotide is a synthetic somatostatin analog used to control the symptoms of carcinoid syndrome.

References

- Small bowel cancer in the United States: changes in epidemiology, treatment, and survival over the last 20 years.

Pharmacology	Gastrointestinal & Nutrition	Carcinoid tumors
Subject	System	Topic

Copyright © UWorld. All rights reserved.

A 34-year-old man is evaluated for several months of epigastric pain that is worse at night and is relieved by eating. The patient has no significant medical history and takes no medications. He does not use tobacco, alcohol, or illicit drugs. The patient immigrated to the United States from China 4 years ago. Vital signs are within normal limits. Physical examination shows mild epigastric tenderness to deep palpation. Upper gastrointestinal endoscopy reveals a 1-cm ulcer in the first portion of the duodenum. Additional testing is pending. In addition to proton pump inhibitor therapy, which of the following therapies would most likely prevent ulcer recurrence in this patient?

- A. Antibiotics
- B. Gastric cytoprotectants
- C. Glucocorticoids
- D. Histamine 2 receptor blockers
- E. Prokinetic agents
- F. Prostaglandin analogues

Submit

A 34-year-old man is evaluated for several months of epigastric pain that is worse at night and is relieved by eating. The patient has no significant medical history and takes no medications. He does not use tobacco, alcohol, or illicit drugs. The patient immigrated to the United States from China 4 years ago. Vital signs are within normal limits. Physical examination shows mild epigastric tenderness to deep palpation. Upper gastrointestinal endoscopy reveals a 1-cm ulcer in the first portion of the duodenum. Additional testing is pending. In addition to proton pump inhibitor therapy, which of the following therapies would most likely prevent ulcer recurrence in this patient?

- ✓ A. Antibiotics (80%)
- B. Gastric cytoprotectants (2%)
- C. Glucocorticoids (0%)
- D. Histamine 2 receptor blockers (9%)
- E. Prokinetic agents (0%)
- F. Prostaglandin analogues (6%)

Omitted
Correct answer
A

80%
Answered correctly

02 secs
Time Spent

02/27/2020
Last Updated

Explanation

***Helicobacter pylori* and duodenal ulcers**

1
2
3
4
5
6
7
8
9
10
11
12
13
14
15
16
17
18
19
20
21
22
23
24
25
26
27
28
29
30
31

Helicobacter pylori and duodenal ulcers

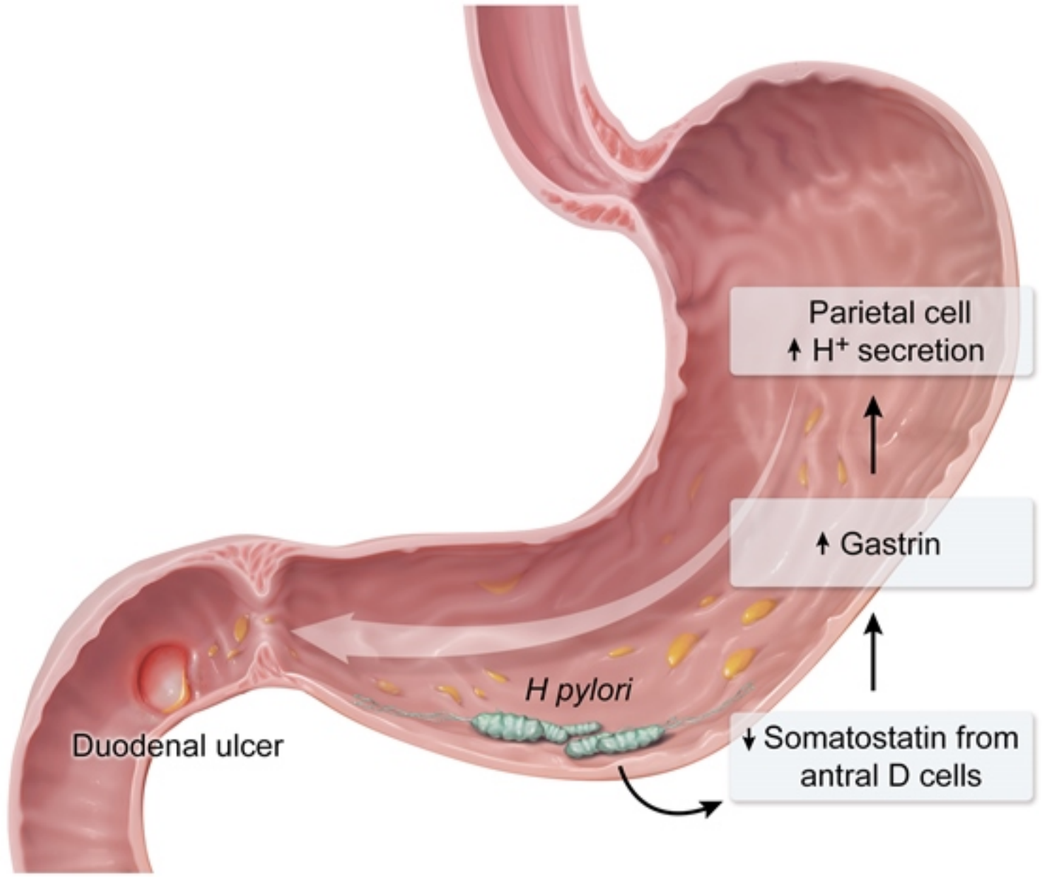

©UWorld

This patient's symptoms and endoscopic findings are consistent with **duodenal peptic ulcer disease** (PUD). Up to 90% of duodenal ulcers are caused by ***Helicobacter pylori*** infection. The remaining cases are typically associated with nonsteroidal anti-inflammatory drug (NSAID) use, which is unlikely in this patient who takes no medications. Over 50% of the world population is colonized with *H pylori*, with a particularly high prevalence in resource-limited countries, including much of Africa, Western Asia, and South America.

This patient's symptoms and endoscopic findings are consistent with **duodenal peptic ulcer disease** (PUD). Up to 90% of duodenal ulcers are caused by ***Helicobacter pylori*** infection. The remaining cases are typically associated with nonsteroidal anti-inflammatory drug (NSAID) use, which is unlikely in this patient who takes no medications. Over 50% of the world population is colonized with *H pylori*, with a particularly high prevalence in resource-limited countries, including much of Africa, Western Asia, and South America.

To reduce the likelihood of PUD recurrence after ulcer healing, *H pylori* infection must be eradicated. Effective regimens typically involve a combination of **antibiotics** (eg, tetracycline, metronidazole) and proton pump inhibitors (eg, omeprazole), often with bismuth subsalicylate (ie, quadruple therapy). The antibiotic regimen can be tailored based on local resistance patterns.

(Choice B) Gastric cytoprotectants (eg, sucralfate) bind to the base of mucosal ulcers and protect them against gastric acid. This can help duodenal ulcers heal but would be less effective in preventing ulcer recurrence than eradication of *H pylori*.

(Choice C) Glucocorticoids should be avoided in patients with PUD as they can promote peptic ulcer formation, especially when combined with NSAIDs.

(Choice D) Proton pump inhibitors suppress gastric acid secretion to a greater extent than histamine H2-receptor blockers (eg, ranitidine), allowing for superior ulcer healing during PUD treatment. However, neither medication would prevent ulcer recurrence (which requires *H pylori* eradication).

(Choice E) Metoclopramide is a dopamine antagonist with prokinetic and antiemetic properties that can be used to treat gastrointestinal motility disorders (eg, gastroparesis) and nausea/vomiting; however, it does not have a significant effect on PUD.

(Choice F) Prostaglandin analogues such as misoprostol are used to prevent NSAID-induced peptic ulcers.

Educational objective:
Most duodenal peptic ulcers are caused by *Helicobacter pylori* infection. The most effective method to prevent disease recurrence is to eradicate the infection with antibiotics (eg, tetracycline, metronidazole), typically in combination with proton pump inhibitors (eg, omeprazole) and, often, bismuth subsalicylate (quadruple therapy).

References

- A review of Helicobacter pylori diagnosis, treatment, and methods to detect eradication.

To reduce the likelihood of PUD recurrence after ulcer healing, *H pylori* infection must be eradicated. Effective regimens typically involve a combination of **antibiotics** (eg, tetracycline, metronidazole) and proton pump inhibitors (eg, omeprazole), often with bismuth subsalicylate (ie, quadruple therapy). The antibiotic regimen can be tailored based on local resistance patterns.

(Choice B) Gastric cytoprotectants (eg, sucralfate) bind to the base of mucosal ulcers and protect them against gastric acid. This can help duodenal ulcers heal but would be less effective in preventing ulcer recurrence than eradication of *H pylori*.

(Choice C) Glucocorticoids should be avoided in patients with PUD as they can promote peptic ulcer formation, especially when combined with NSAIDs.

(Choice D) Proton pump inhibitors suppress gastric acid secretion to a greater extent than histamine H2-receptor blockers (eg, ranitidine), allowing for superior ulcer healing during PUD treatment. However, neither medication would prevent ulcer recurrence (which requires *H pylori* eradication).

(Choice E) Metoclopramide is a dopamine antagonist with prokinetic and antiemetic properties that can be used to treat gastrointestinal motility disorders (eg, gastroparesis) and nausea/vomiting; however, it does not have a significant effect on PUD.

(Choice F) Prostaglandin analogues such as misoprostol are used to prevent NSAID-induced peptic ulcers.

Educational objective:
Most duodenal peptic ulcers are caused by *Helicobacter pylori* infection. The most effective method to prevent disease recurrence is to eradicate the infection with antibiotics (eg, tetracycline, metronidazole), typically in combination with proton pump inhibitors (eg, omeprazole) and, often, bismuth subsalicylate (quadruple therapy).

References

- A review of Helicobacter pylori diagnosis, treatment, and methods to detect eradication.

Pharmacology	Gastrointestinal & Nutrition	Peptic ulcer disease
Subject	System	Topic

Copyright © UWorld. All rights reserved.

1
2
3
4
5
6
7
8
9
10
11
12
13
14
15
16
17
18
19
20
21
22
23
24
25
26
27
28
29
30
31

A group of researchers investigates why individuals who have undergone gastrectomy lose more weight than can be explained by dietary changes alone. They recruit several subjects who have had distal gastrectomy for benign gastric-outlet obstruction for a clinical study. Control subjects with matching baseline weight are also enrolled and are instructed to follow a diet similar to that of the postgastrectomy subjects during the study period. Plasma levels of several hormones are serially measured over 24 hours in both groups. Levels of one of the hormones are shown in the graph below:

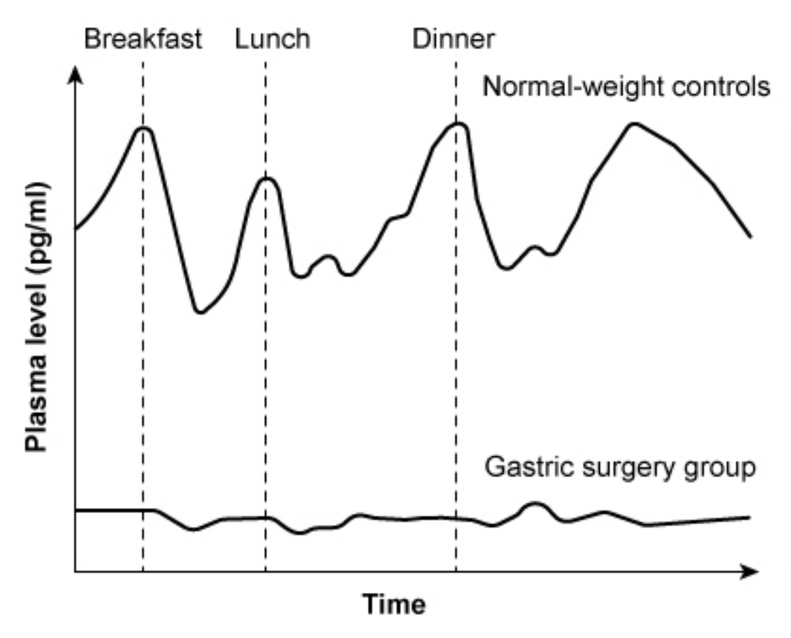

This profile most likely represents which of the following hormones?

A. Cholecystokinin

B. Gastrin

C. Ghrelin

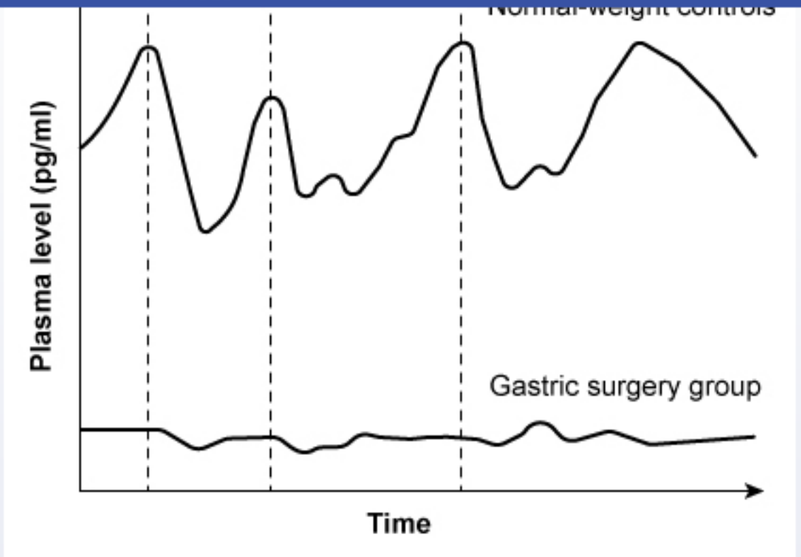

This profile most likely represents which of the following hormones?

- A. Cholecystokinin
- B. Gastrin
- C. Ghrelin
- D. Insulin
- E. Leptin
- F. Motilin

Submit

1
2
3
4
5
6
7
8
9
10
11
12
13
14
15
16
17
18
19
20
21
22
23
24
25
26
27
28
29
30
31

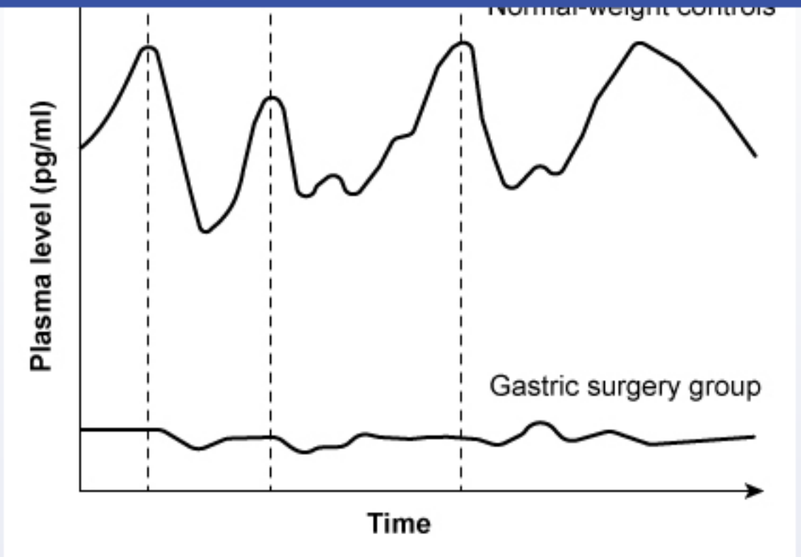

This profile most likely represents which of the following hormones?

- A. Cholecystokinin (3%)
- B. Gastrin (21%)
- ✓ C. Ghrelin (63%)
- D. Insulin (4%)
- E. Leptin (4%)
- F. Motilin (1%)

Omitted
Correct answer

63%
Answered correctly

09 secs
Time Spent

03/03/2020
Last Updated

1
2
3
4
5
6
7
8
9
10
11
12
13
14
15
16
17
18
19
20
21
22
23
24
25
26
27
28
29
30
31

Appetite hormones: leptin & ghrelin

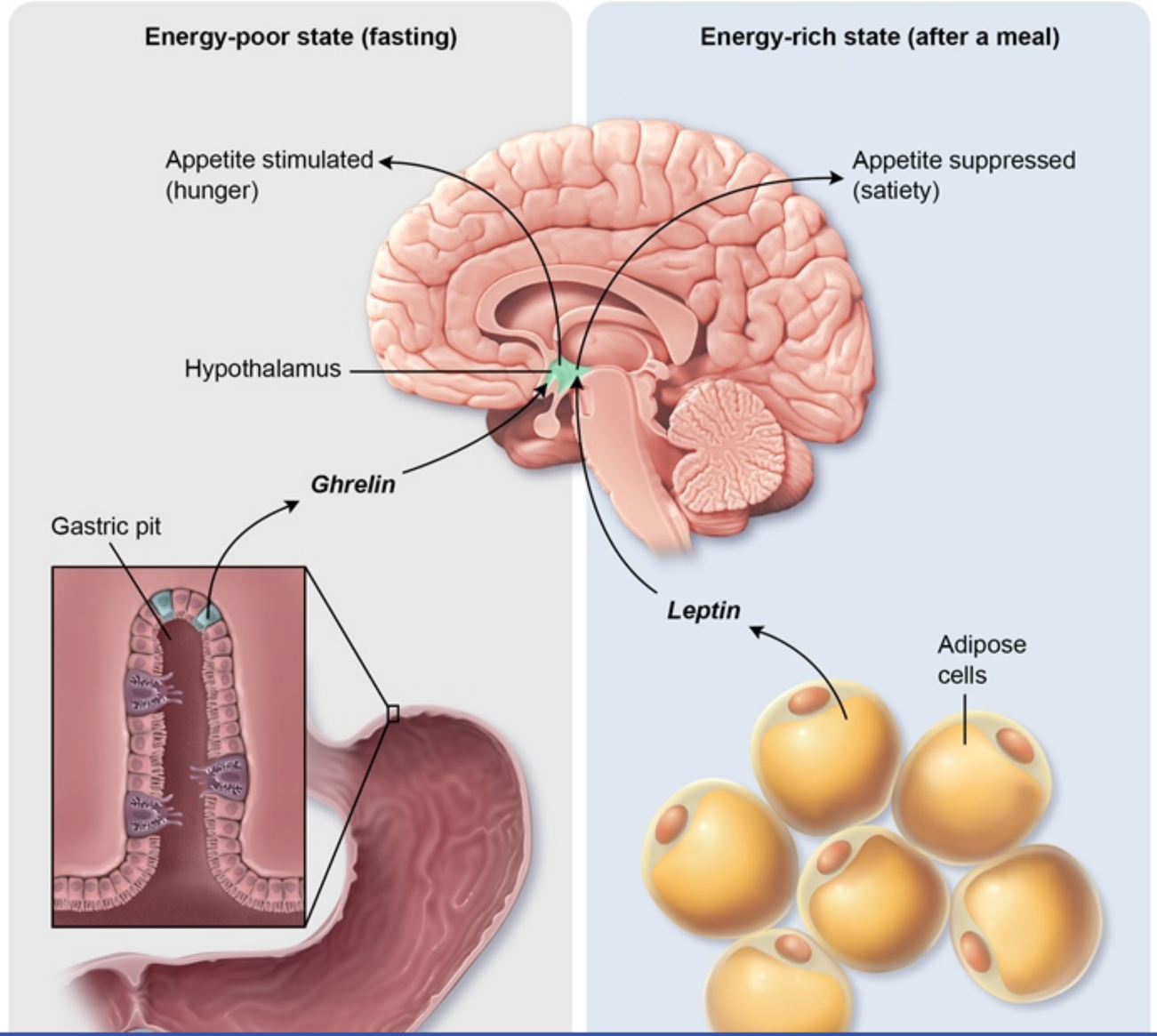

The 24-hour hormone levels in the control subjects show increasing secretion leading up to meals, followed by a sharp postprandial drop. However, the subjects who have undergone gastrectomy show lower baseline levels with attenuation of meal-related fluctuations. This pattern suggests that the hormone is likely secreted in the stomach and suppressed by food intake, which is consistent with the secretory pattern of **ghrelin**.

Ghrelin is **produced primarily in the stomach** in response to **fasting**; levels surge leading up to meals and fall after eating. Ghrelin **stimulates appetite** and promotes **weight gain**. Caloric restriction and falling fat stores lead to increased ghrelin levels (along with decreased leptin and insulin levels), which limits weight loss from dietary modification alone. However, patients who have undergone bariatric procedures that remove a portion of the stomach (eg, roux-en-Y gastric bypass, sleeve **gastrectomy**) can lose a significant number of ghrelin-secreting cells. This leads to **lower ghrelin levels** and less stimulation of appetite in response to fasting, promoting weight loss.

(Choice A) Cholecystokinin stimulates gallbladder contraction and pancreatic enzyme and bicarbonate secretion. It is secreted in the duodenum and jejunum in response to fat and protein in the intestinal lumen, and levels rise following meals.

(Choice B) Gastrin stimulates parietal cell acid production. It is secreted primarily by G cells of the gastric antrum in response to vagal activity, gastric distension, and the presence of amino acids in the gastric lumen. Although gastrin production would be lower in the postgastrectomy subjects, gastrin levels normally rise (not fall) in response to meals.

(Choice D) Insulin levels rise rapidly in response to increased blood glucose following meals then gradually fall back to baseline. Insulin is secreted by pancreatic beta cells and would not be drastically reduced following gastrectomy.

(Choice E) Leptin is produced primarily by fat cells in response to short-term food intake and long-term adequacy of fat stores. It acts on the hypothalamus to decrease appetite (obesity blunts this action). During fasting states, leptin levels fall.

(Choice F) Motilin stimulates smooth muscle contraction in the upper gastrointestinal tract and generally increases gastric motility. Although secretion appears to increase during fasting and decrease following meals, it is produced primarily in the duodenal mucosa rather than the stomach.

Educational objective:
Ghrelin is produced in the stomach in response to fasting; levels surge leading up to meals and fall after eating. Ghrelin stimulates appetite and promotes weight gain. Patients who have undergone gastrectomy have reduced ghrelin levels, leading to weight loss.

References

1
2
3
4
5
6
7
8
9
10
11
12
13
14
15
16
17
18
19
20
21
22
23
24
25
26
27
28
29
30
31

portion of the stomach (eg, roux-en-Y gastric bypass, sleeve **gastrectomy**) can lose a significant number of ghrelin-secreting cells. This leads to **lower ghrelin levels** and less stimulation of appetite in response to fasting, promoting weight loss.

(Choice A) Cholecystokinin stimulates gallbladder contraction and pancreatic enzyme and bicarbonate secretion. It is secreted in the duodenum and jejunum in response to fat and protein in the intestinal lumen, and levels rise following meals.

(Choice B) Gastrin stimulates parietal cell acid production. It is secreted primarily by G cells of the gastric antrum in response to vagal activity, gastric distension, and the presence of amino acids in the gastric lumen. Although gastrin production would be lower in the postgastrectomy subjects, gastrin levels normally rise (not fall) in response to meals.

(Choice D) Insulin levels rise rapidly in response to increased blood glucose following meals then gradually fall back to baseline. Insulin is secreted by pancreatic beta cells and would not be drastically reduced following gastrectomy.

(Choice E) Leptin is produced primarily by fat cells in response to short-term food intake and long-term adequacy of fat stores. It acts on the hypothalamus to decrease appetite (obesity blunts this action). During fasting states, leptin levels fall.

(Choice F) Motilin stimulates smooth muscle contraction in the upper gastrointestinal tract and generally increases gastric motility. Although secretion appears to increase during fasting and decrease following meals, it is produced primarily in the duodenal mucosa rather than the stomach.

Educational objective:
Ghrelin is produced in the stomach in response to fasting; levels surge leading up to meals and fall after eating. Ghrelin stimulates appetite and promotes weight gain. Patients who have undergone gastrectomy have reduced ghrelin levels, leading to weight loss.

References

- The impact of laparoscopic sleeve gastrectomy on plasma ghrelin levels: a systematic review.

Pharmacology	Gastrointestinal & Nutrition	Obesity
Subject	System	Topic

Copyright © UWorld. All rights reserved.

1
2
3
4
5
6
7
8
9
10
11
12
13
14
15
16
17
18
19
20
21
22
23
24
25
26
27
28
29
30
31

Exhibit Display

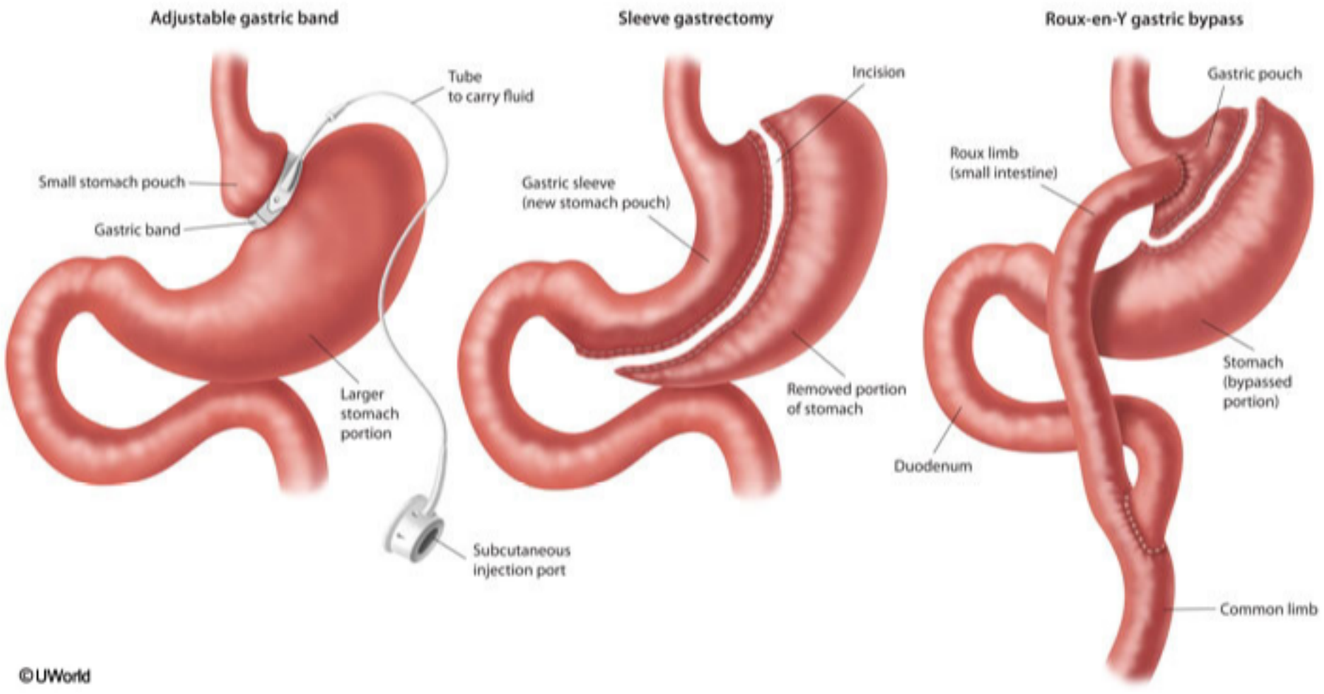

Zoom In Zoom Out Reset Add To Flash Card

(Choice E) Motilin stimulates smooth muscle contraction in the upper gastrointestinal tract and generally increases gastric motility. Although

1
2
3
4
5
6
7
8
9
10
11
12
13
14
15
16
17
18
19
20
21
22
23
24
25
26
27
28
29
30
31

A 38-year-old woman comes to the office to discuss motion sickness. She is currently feeling well. The patient is planning a vacation cruise and has previously experienced severe nausea and vomiting while sailing. She has 4 children, and her past medical history is notable only for a tubal ligation. The patient does not smoke and drinks only moderate quantities of alcohol. She is not currently taking any medications. Physical examination, including otologic and neurologic examinations, is normal. After the appropriate drug therapy is recommended, this patient should be counseled regarding which of the following side effects?

A. Cough

B. Diarrhea

C. Dry mouth

D. Frequent urination

E. Nasal congestion

Submit

A 38-year-old woman comes to the office to discuss motion sickness. She is currently feeling well. The patient is planning a vacation cruise and has previously experienced severe nausea and vomiting while sailing. She has 4 children, and her past medical history is notable only for a tubal ligation. The patient does not smoke and drinks only moderate quantities of alcohol. She is not currently taking any medications. Physical examination, including otologic and neurologic examinations, is normal. After the appropriate drug therapy is recommended, this patient should be counseled regarding which of the following side effects?

- A. Cough (1%)
- B. Diarrhea (6%)
- ✓ C. Dry mouth (87%)
- D. Frequent urination (2%)
- E. Nasal congestion (1%)

Omitted
Correct answer
C

87%
Answered correctly

02 secs
Time Spent

04/19/2020
Last Updated

Explanation

Characteristics of antiemetic drugs		
Drug class	Examples	Clinical uses

Explanation

Characteristics of antiemetic drugs		
Drug class	**Examples**	**Clinical uses**
Antimuscarinics (anticholinergics)	• Scopolamine	Motion sickness Hyperemesis gravidarum (promethazine)
Antihistamines	• Diphenhydramine • Meclizine • Promethazine	
Dopamine receptor antagonists	• Prochlorperazine • Metoclopramide	Chemotherapy-induced emesis
Serotonin (5-HT_3) receptor antagonists	• Ondansetron • Granisetron	
Neurokinin 1 (NK1) receptor antagonists	• Aprepitant • Fosaprepitant	

©UWorld

Perception of motion and orientation is determined by input from the vestibular, visual, and somatosensory systems. These 3 systems are usually congruent, but conflicting input can lead to **motion sickness**, characterized by nausea, dizziness, and autonomic symptoms (eg, diaphoresis). Integration of these sensory pathways occurs in the **vestibular nuclei** via muscarinic and histaminic neurotransmission. As such, **antimuscarinic**

antagonists	• Granisetron	induced emesis
Neurokinin 1 (NK1) receptor antagonists	• Aprepitant • Fosaprepitant	

©UWorld

Perception of motion and orientation is determined by input from the vestibular, visual, and somatosensory systems. These 3 systems are usually congruent, but conflicting input can lead to **motion sickness**, characterized by nausea, dizziness, and autonomic symptoms (eg, diaphoresis). Integration of these sensory pathways occurs in the **vestibular nuclei** via muscarinic and histaminic neurotransmission. As such, **antimuscarinic** agents (eg, scopolamine) and first-generation **antihistamines** (eg, meclizine, dimenhydrinate) are most effective for management of motion sickness. **Anticholinergic side effects** are common with these medications and may include blurry vision, dry mouth, urinary retention, and constipation.

(Choices A, D, and E) Cough, frequent urination, and nasal congestion are characteristic of stimulation rather than blockade of muscarinic pathways.

(Choice B) Diarrhea may be seen with dopamine receptor antagonists (eg, metoclopramide), but these drugs are primarily used for visceral (eg, diabetic gastroparesis), rather than vestibular, nausea.

Educational objective:
Antimuscarinic agents and antihistamines with antimuscarinic action are most effective for motion sickness prevention.

References

- Scopolamine (hyoscine) for preventing and treating motion sickness.

Pharmacology	Gastrointestinal & Nutrition	Motion sickness
Subject	System	Topic

Copyright © UWorld. All rights reserved.

1
2
3
4
5
6
7
8
9
10
11
12
13
14
15
16
17
18
19
20
21
22
23
24
25
26
27
28
29
30
31

A 32-year-old man is evaluated for recurrent nausea and vomiting. The patient has nausea and upper abdominal discomfort after meals and feels full even after eating a small amount of food. He also has experienced several episodes of vomiting of undigested food particles but has had no fever or diarrhea. The patient has a history of type 1 diabetes mellitus and diabetic neuropathy. Physical examination shows a clear oropharynx. The abdomen is soft, nondistended, and nontender with no organomegaly. Bowel sounds are normoactive. Stool testing for occult blood is negative. Upper gastrointestinal endoscopy reveals no abnormalities. Treatment with an oral medication is initiated, but it is stopped after the patient experiences abnormal involuntary movements. A macrolide antibiotic is prescribed, which improves his symptoms. Which of following mechanisms is most likely responsible for the improvement in this patient's symptoms?

A. Agonistic activity on motilin receptors

B. Blockade of gastrointestinal muscarinic receptors

C. Increase in intestinal fluid secretion

D. Protective effect on gastric mucosa

E. Suppression of intestinal bacterial growth

Submit

A 32-year-old man is evaluated for recurrent nausea and vomiting. The patient has nausea and upper abdominal discomfort after meals and feels full even after eating a small amount of food. He also has experienced several episodes of vomiting of undigested food particles but has had no fever or diarrhea. The patient has a history of type 1 diabetes mellitus and diabetic neuropathy. Physical examination shows a clear oropharynx. The abdomen is soft, nondistended, and nontender with no organomegaly. Bowel sounds are normoactive. Stool testing for occult blood is negative. Upper gastrointestinal endoscopy reveals no abnormalities. Treatment with an oral medication is initiated, but it is stopped after the patient experiences abnormal involuntary movements. A macrolide antibiotic is prescribed, which improves his symptoms. Which of following mechanisms is most likely responsible for the improvement in this patient's symptoms?

- ✓ A. Agonistic activity on motilin receptors (63%)
- B. Blockade of gastrointestinal muscarinic receptors (6%)
- C. Increase in intestinal fluid secretion (2%)
- D. Protective effect on gastric mucosa (3%)
- E. Suppression of intestinal bacterial growth (23%)

Omitted
Correct answer
A

63%
Answered correctly

02 secs
Time Spent

01/28/2020
Last Updated

Explanation

This patient with diabetes mellitus has postprandial nausea, vomiting of undigested food, bloating, and early satiety, raising strong suspicion for **diabetic gastroparesis**, an autonomic neuropathy of the gastrointestinal tract marked by delayed gastric emptying in the absence of mechanical obstruction (eg, normal esophagogastroduodenoscopy [EGD]). Metoclopramide, a dopamine 2 receptor antagonist, can improve symptoms but is

For patients with gastroparesis who cannot tolerate metoclopramide, **erythromycin**, a macrolide antibiotic, can be used as an alternate prokinetic agent. The prokinetic effects of erythromycin stem from the **activation of the motilin receptor** in the smooth muscle of the upper digestive tract, which results in coordinated peristaltic contractions that begin in the stomach and move through the entire upper digestive system (thereby propelling food into the colon).

When used as an antibiotic, erythromycin can cause significant abdominal cramping, but in the setting of gastroparesis, the prokinetic effects can be leveraged to improve gastric emptying and ameliorate gastroparesis symptoms. However, the agonist effects of erythromycin diminish over time (tachyphylaxis) so it is generally used for short periods (<4 weeks).

(Choices B and C) Patients with irritable bowel syndrome (IBS) who have significant gastrointestinal bloating symptoms can be treated with antispasmodic medications (eg, dicycloverine) that block gastrointestinal muscarinic receptors. Those with constipation-predominant IBS are sometimes treated with lubiprostone, a chloride channel activator, to increase intestinal fluid secretion. IBS is usually marked by periods of diarrhea and/or constipation and abdominal bloating; early satiety and vomiting of undigested food would be atypical.

(Choice D) Peptic ulcer disease (PUD) is treated with medications (eg, proton pump inhibitor, sucralfate) that have a protective effect on the gastrointestinal mucosa. Although PUD can occasionally cause nausea, vomiting, and early satiety due to gastric outlet obstruction, most patients have significant upper abdominal pain. In addition, an EGD would show a gastric or duodenal ulcer.

(Choice E) Patients with small intestinal bacterial overgrowth (SIBO)—colonization of the small intestine with colonic bacteria—often develop bloating, abdominal discomfort, flatulence, and/or diarrhea. However, early satiety and vomiting of undigested food would be atypical. In addition, SIBO is generally treated with rifaximin or neomycin.

Educational objective:
Erythromycin stimulates upper gastrointestinal motility by acting as an agonist on motilin receptors in the muscularis externa. Therefore, it can be used to treat gastroparesis (ie, delayed gastric emptying), a condition that frequently occurs in patients with long standing diabetes mellitus.

Pharmacology	Gastrointestinal & Nutrition	Gastroparesis
Subject	System	Topic

Copyright © UWorld. All rights reserved.

1
2
3
4
5
6
7
8
9
10
11
12
13
14
15
16
17
18
19
20
21
22
23
24
25
26
27
28
29
30
31

The mother of a 2-year-old boy calls the office for guidance regarding his recent illness. He has passed 4-6 stools daily over the last 2 days. The feces are liquid and contain no blood or mucus. His highest temperature reading at home was 37.8 C (100 F). He is eating, drinking, and being playful as usual. The patient has no prior medical problems and is up to date with vaccinations. He recently began going to day care. The mother is advised to bring the patient to the office for further evaluation. While awaiting medical evaluation, which of the following oral fluids is most effective to prevent dehydration in this patient?

A. Chicken broth with added salt

B. Diluted cow's milk

C. Filtered water with no added solutes

D. Noncarbonated sports drinks

E. Sodium-glucose solution

F. Sugary fruit juices

Submit

The mother of a 2-year-old boy calls the office for guidance regarding his recent illness. He has passed 4-6 stools daily over the last 2 days. The feces are liquid and contain no blood or mucus. His highest temperature reading at home was 37.8 C (100 F). He is eating, drinking, and being playful as usual. The patient has no prior medical problems and is up to date with vaccinations. He recently began going to day care. The mother is advised to bring the patient to the office for further evaluation. While awaiting medical evaluation, which of the following oral fluids is most effective to prevent dehydration in this patient?

- A. Chicken broth with added salt (8%)
- B. Diluted cow's milk (0%)
- C. Filtered water with no added solutes (10%)
- D. Noncarbonated sports drinks (21%)
- ✓ E. Sodium-glucose solution (58%)
- F. Sugary fruit juices (0%)

Omitted
Correct answer
E

58%
Answered correctly

02 secs
Time Spent

02/03/2020
Last Updated

Explanation

Humans consume approximately 2 L of fluid each day and secrete an additional 7 L of fluid from upper digestive organs (eg, salivary glands, stomach, pancreas, gallbladder). Nearly all of this fluid is reabsorbed from the gastrointestinal lumen by the small intestine epithelium. The **osmotic gradient** for water reabsorption is largely established by the **active cotransport of sodium** into the apical end of enterocytes coupled with chloride, glucose, or amino acids. Sodium is then transported out of the basolateral end of the enterocyte (sodium/potassium ATPase), which

Humans consume approximately 2 L of fluid each day and secrete an additional 7 L of fluid from upper digestive organs (eg, salivary glands, stomach, pancreas, gallbladder). Nearly all of this fluid is reabsorbed from the gastrointestinal lumen by the small intestine epithelium. The **osmotic gradient** for water reabsorption is largely established by the **active cotransport of sodium** into the apical end of enterocytes coupled with chloride, glucose, or amino acids. Sodium is then transported out of the basolateral end of the enterocyte (sodium/potassium ATPase), which pulls water down its osmotic gradient from the gastrointestinal lumen through the tight junctions between enterocytes and into the lamina propria (and ultimately the bloodstream).

This young patient who recently began going to day care likely has **acute infectious diarrhea** of a viral etiology (eg, rotavirus, norovirus). Infections that target the small intestine cause watery diarrhea by blocking the active transport of sodium chloride into the enterocyte or by increasing chloride excretion into the gastrointestinal lumen (mediated by elevated intracellular cyclic AMP, cyclic GMP, or calcium). In this setting, oral rehydration with a hypotonic, **equimolar sodium-glucose solution** maximizes water and sodium reabsorption by the remaining functional enterocytes, and is the most effective oral therapy for maintaining volume and electrolyte status in children with acute infectious diarrhea.

(Choice A) Chicken broth with added salt is a hyperosmolar solution that can cause hypernatremia and is, therefore, not recommended.

(Choice B) Diluted or undiluted cow's milk is not an effective rehydration solution during acute diarrhea due to impaired digestion of milk components, which can promote osmotic diarrhea.

(Choice C) Filtered water alone is not usually sufficient to prevent dehydration in patients with acute infectious diarrhea due to the increased solute load in the gastrointestinal lumen, which causes most of the free water to be retained in the intestine and excreted in the feces.

(Choices D and F) Although sports drinks and sugary fruit juices contain glucose, they often have significantly lower sodium concentrations and high osmolality. This ultimately reduces water reabsorption and may promote osmotic diarrhea.

Educational objective:
Children with watery diarrhea should be treated with oral rehydration solutions containing hypotonic, equimolar concentrations of sodium and glucose to help prevent dehydration and electrolyte abnormalities.

References

- Managing acute gastroenteritis among children: oral rehydration, maintenance, and nutritional therapy.

pulls water down its osmotic gradient from the gastrointestinal lumen through the tight junctions between enterocytes and into the lamina propria (and ultimately the bloodstream).

This young patient who recently began going to day care likely has **acute infectious diarrhea** of a viral etiology (eg, rotavirus, norovirus). Infections that target the small intestine cause watery diarrhea by blocking the active transport of sodium chloride into the enterocyte or by increasing chloride excretion into the gastrointestinal lumen (mediated by elevated intracellular cyclic AMP, cyclic GMP, or calcium). In this setting, oral rehydration with a hypotonic, **equimolar sodium-glucose solution** maximizes water and sodium reabsorption by the remaining functional enterocytes, and is the most effective oral therapy for maintaining volume and electrolyte status in children with acute infectious diarrhea.

(Choice A) Chicken broth with added salt is a hyperosmolar solution that can cause hypernatremia and is, therefore, not recommended.

(Choice B) Diluted or undiluted cow's milk is not an effective rehydration solution during acute diarrhea due to impaired digestion of milk components, which can promote osmotic diarrhea.

(Choice C) Filtered water alone is not usually sufficient to prevent dehydration in patients with acute infectious diarrhea due to the increased solute load in the gastrointestinal lumen, which causes most of the free water to be retained in the intestine and excreted in the feces.

(Choices D and F) Although sports drinks and sugary fruit juices contain glucose, they often have significantly lower sodium concentrations and high osmolality. This ultimately reduces water reabsorption and may promote osmotic diarrhea.

Educational objective:
Children with watery diarrhea should be treated with oral rehydration solutions containing hypotonic, equimolar concentrations of sodium and glucose to help prevent dehydration and electrolyte abnormalities.

References

- Managing acute gastroenteritis among children: oral rehydration, maintenance, and nutritional therapy.

Pharmacology	Gastrointestinal & Nutrition	Acute diarrhea
Subject	System	Topic

Copyright © UWorld. All rights reserved.

1
2
3
4
5
6
7
8
9
10
11
12
13
14
15
16
17
18
19
20
21
22
23
24
25
26
27
28
29
30
31

A 16-year-old boy is brought to the office by his parents due to tremors and difficulty walking. Over the past year, his school performance has declined, and he has been moodier and more impulsive. His parents also note that he has been sleeping more than usual and has had a poor appetite for the past 2 months. Approximately 3 weeks ago, the patient developed a tremor in both hands that is most prominent when he reaches for an object or tries to write. The tremor has worsened significantly over the past week, and he has developed an unsteady, broad-based gait. Laboratory studies reveal elevated serum transaminases and 24-hour urinary copper excretion. The patient is prescribed penicillamine therapy. This medication primarily works through which of the following mechanisms?

A. Decreasing intestinal absorption of copper
B. Increasing urinary excretion of copper
C. Repletion of intracellular glutathione
D. Stimulation of defective gene expression
E. Stimulation of canalicular transport proteins

Submit

A 16-year-old boy is brought to the office by his parents due to tremors and difficulty walking. Over the past year, his school performance has declined, and he has been moodier and more impulsive. His parents also note that he has been sleeping more than usual and has had a poor appetite for the past 2 months. Approximately 3 weeks ago, the patient developed a tremor in both hands that is most prominent when he reaches for an object or tries to write. The tremor has worsened significantly over the past week, and he has developed an unsteady, broad-based gait. Laboratory studies reveal elevated serum transaminases and 24-hour urinary copper excretion. The patient is prescribed penicillamine therapy. This medication primarily works through which of the following mechanisms?

- A. Decreasing intestinal absorption of copper (36%)
- ✓ B. Increasing urinary excretion of copper (57%)
- C. Repletion of intracellular glutathione (2%)
- D. Stimulation of defective gene expression (0%)
- E. Stimulation of canalicular transport proteins (3%)

Omitted
Correct answer
B

57%
Answered correctly

02 secs
Time Spent

07/01/2020
Last Updated

Explanation

Wilson disease	
Pathogenesis	• Autosomal recessive mutation of *ATP7B* → hepatic copper accumulation → leak from damaged hepatocytes → deposits

Wilson disease	
Pathogenesis	• Autosomal recessive mutation of *ATP7B* → hepatic copper accumulation → leak from damaged hepatocytes → deposits in tissues (eg, basal ganglia, cornea)
Clinical findings	• Hepatic (acute liver failure, chronic hepatitis, cirrhosis) • Neurologic (parkinsonism, gait disturbance, dysarthria) • Psychiatric (depression, personality changes, psychosis)
Diagnosis	• ↓ Ceruloplasmin & ↑ urinary copper excretion • Kayser-Fleischer rings on slit-lamp examination • ↑ Copper content on liver biopsy
Treatment	• Chelators (eg, D-penicillamine, trientine) • Zinc (interferes with copper absorption)

This patient has **Wilson disease**, an autosomal recessive disorder characterized by excessive copper deposition in the liver, basal ganglia, and cornea.

Copper is an essential nutrient that is absorbed in the intestines, metabolized by hepatocytes, and excreted in the bile. Pathogenesis of Wilson disease involves impaired hepatocellular copper transport, which results in **decreased biliary excretion of copper**. The resultant increase in intracellular copper causes oxidative stress and apoptosis of hepatocytes, which leads to liver dysfunction (eg, elevated transaminases, liver failure). Excess copper is then released into the bloodstream and deposited into extrahepatic tissues, causing neurologic (eg, tremor, ataxia) and psychiatric symptoms (eg, impulsivity, depressive symptoms). Although renal excretion of copper in healthy patients is extremely low, the relative increase in serum copper in Wilson disease results in increased urinary excretion of copper, as seen in this patient.

First-line treatment of Wilson disease is with **penicillamine**, a **copper chelating agent**. Penicillamine binds free copper as well as reduces copper bound to other proteins. This reduction preferentially increases affinity of copper to the chelating agent. The chelator-copper complex is soluble, thereby **increasing urinary copper excretion**.

(Choice A) Zinc decreases intestinal absorption of copper and can be used in conjunction with penicillamine to treat Wilson disease.

cornea.

Copper is an essential nutrient that is absorbed in the intestines, metabolized by hepatocytes, and excreted in the bile. Pathogenesis of Wilson disease involves impaired hepatocellular copper transport, which results in **decreased biliary excretion of copper**. The resultant increase in intracellular copper causes oxidative stress and apoptosis of hepatocytes, which leads to liver dysfunction (eg, elevated transaminases, liver failure). Excess copper is then released into the bloodstream and deposited into extrahepatic tissues, causing neurologic (eg, tremor, ataxia) and psychiatric symptoms (eg, impulsivity, depressive symptoms). Although renal excretion of copper in healthy patients is extremely low, the relative increase in serum copper in Wilson disease results in increased urinary excretion of copper, as seen in this patient.

First-line treatment of Wilson disease is with **penicillamine**, a **copper chelating agent**. Penicillamine binds free copper as well as reduces copper bound to other proteins. This reduction preferentially increases affinity of copper to the chelating agent. The chelator-copper complex is soluble, thereby **increasing urinary copper excretion**.

(Choice A) Zinc decreases intestinal absorption of copper and can be used in conjunction with penicillamine to treat Wilson disease.

(Choice C) Acetaminophen overdose causes hepatotoxicity via depletion of intracellular glutathione, which can be reversed with N-acetylcysteine treatment.

(Choices D and E) Gene therapy could theoretically improve or cure Wilson disease by transferring a functional copper transport protein gene into hepatocytes. This would restore their ability to transport excess copper into secretory vesicles, promoting exocytosis of copper into the bile canaliculi.

Educational objective:
Penicillamine, a first-line treatment for Wilson disease, is a copper chelating agent that increases the urinary excretion of copper.

References

- Clinical management of Wilson disease.

Pharmacology	Gastrointestinal & Nutrition	Wilson disease
Subject	System	Topic

Copyright © UWorld. All rights reserved.

cornea.

Exhibit Display

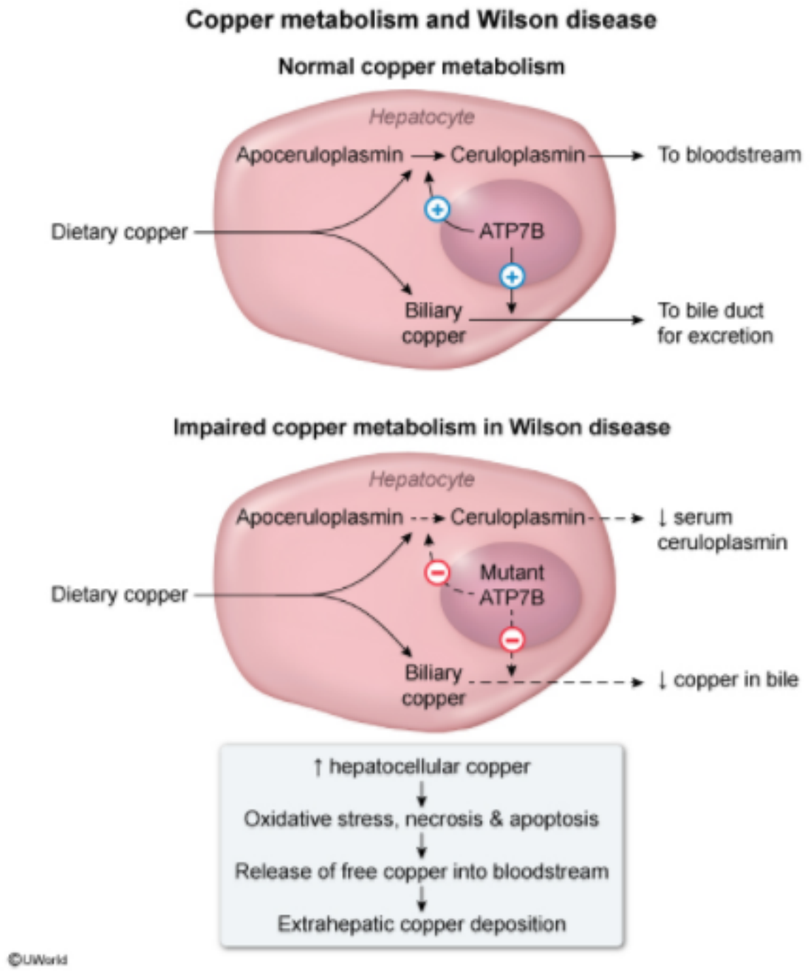

Zoom In Zoom Out Reset Add To Flash Card